

# Recommendations for Evaluation of Prosthetic Valves With Echocardiography and Doppler Ultrasound

A Report From the American Society of Echocardiography's Guidelines and Standards Committee and the Task Force on Prosthetic Valves, Developed in Conjunction With the American College of Cardiology Cardiovascular Imaging Committee, Cardiac Imaging Committee of the American Heart Association, the European Association of Echocardiography, a registered branch of the European Society of Cardiology, the Japanese Society of Echocardiography and the Canadian Society of Echocardiography, Endorsed by the American College of Cardiology Foundation, American Heart Association, European Association of Echocardiography, a registered branch of the European Society of Cardiology, the Japanese Society of Echocardiography, and Canadian Society of Echocardiography

William A. Zoghbi, MD, FASE, Chair, John B. Chambers, MD,\* Jean G. Dumesnil, MD,† Elyse Foster, MD,‡ John S. Gottdiener, MD, FASE, Paul A. Grayburn, MD, Bijoy K. Khandheria, MBBS, FASE, Robert A. Levine, MD, Gerald Ross Marx, MD, FASE, Fletcher A. Miller, Jr., MD, FASE, Satoshi Nakatani, MD, PhD,§ Miguel A. Quiñones, MD, Harry Rakowski, MD, FASE, L. Leonardo Rodriguez, MD, Madhav Swaminathan, MD, FASE, Alan D. Waggoner, MHS, RDCS, Neil J. Weissman, MD, FASE,|| and Miguel Zabalgaitia, MD, *Houston and Dallas, Texas; London, United Kingdom; Quebec City, Quebec, Canada; San Francisco, California; Baltimore, Maryland; Scottsdale, Arizona; Boston, Massachusetts; Rochester, Minnesota; Suita, Japan; Toronto, Ontario, Canada; Cleveland, Ohio; Durham, North Carolina; St Louis, Missouri; Washington, DC; Springfield, Illinois*

From the Methodist DeBakey Heart and Vascular Center, Houston, Texas (W.A.Z., M.A.Q.); St Thomas Hospital, London, United Kingdom (J.B.C.); Hospital Laval, Quebec City, Quebec, Canada (J.G.D.); the University of California, San Francisco, San Francisco, California (E.F.); the University of Maryland Hospital, Baltimore, Maryland (J.S.G.); Baylor University Medical Center, Dallas, Texas (P.A.G.); Mayo Clinic, Scottsdale, Arizona (B.K.K.); Massachusetts General Hospital, Boston, Massachusetts (R.A.L.); Harvard School of Medicine/Boston Children's Hospital, Boston, Massachusetts (G.R.M.); the Mayo Clinic, Rochester, Minnesota (F.A.M.); Osaka University Graduate School of Medicine, Suita, Japan (S.N.); Toronto General Hospital, Toronto, Ontario, Canada (H.R.); the Cleveland Clinic, Cleveland, Ohio (L.L.R.); Duke University Medical Center, Durham, North Carolina (M.S.); Washington University School of Medicine, St Louis, Missouri (A.D.W.); Washington Hospital Center, Washington, DC (N.J.W.); and Prairie Cardiovascular Consultants, Springfield, Illinois (M.Z.).

Reprint requests: American Society of Echocardiography, 2100 Gateway Centre Boulevard, Suite 310, Morrisville, NC 27560 (E-mail: [ase@asecho.org](mailto:ase@asecho.org)).

\* Representing the European Association of Echocardiography. † Representing the Canadian Society of Echocardiography. ‡ Representing the Cardiac Imaging Committee of the American Heart Association. § Representing the Japanese Society of Echocardiography. || Representing the American College of Cardiology Cardiovascular Imaging Committee.

0894-7317/\$36.00

Copyright 2009 by the American Society of Echocardiography.

doi:10.1016/j.echo.2009.07.013

## Accreditation Statement:

The American Society of Echocardiography is accredited by the Accreditation Council for Continuing Medical Education to provide continuing medical education for physicians.

The ASE designates this educational activity for a maximum of 1 AMA PRA Category 1 Credit™. Physicians should only claim credit commensurate with the extent of their participation in the activity.

The American Registry of Diagnostic Medical Sonographers and Cardiovascular Credentialing International recognize the ASE's certificates and have agreed to honor the credit hours toward their registry requirements for sonographers.

The ASE is committed to ensuring that its educational mission and all sponsored educational programs are not influenced by the special interests of any corporation or individual, and its mandate is to retain only those authors whose financial interests can be effectively resolved to maintain the goals and educational integrity of the activity. Although a monetary or professional affiliation with a corporation does not necessarily influence an author's presentation, the essential areas and policies of the ACCME require that any relationships that could possibly conflict with the educational value of an activity be resolved prior to publication and disclosed to the audience. Disclosures of faculty and commercial support relationships, if any, have been indicated.

## Target Audience:

This activity is designed for all cardiovascular physicians and cardiac sonographers with a primary interest and knowledge base in the field of echocardiography. In addition, residents, researchers, clinicians, intensivists, and other medical professionals with specific interest in cardiac ultrasound will find this activity beneficial.

## Objectives:

Upon completing this article, participants will be better able to:

1. Name the components of a complete imaging and Doppler evaluation for prosthetic valve function.
2. Identify the components of an integrative approach to assessing prosthetic aortic and mitral valve stenosis and regurgitation.
3. Identify the components of an integrative approach to assessing prosthetic pulmonary and tricuspid valve stenosis and regurgitation.
4. Describe the pitfalls and limitations of the evaluation of prosthetic valve function.
5. Recognize the special aspects of the pediatric population that add complexity to the evaluation of prosthetic valve function.

**Author Disclosures:**

Elyse Foster receives research and grant support from Evalve (Menlo Park, CA), Boston Scientific Corporation (Natick, MA), and Evidence Based Research, Inc (Vienna, VA). Paul A. Grayburn is the Associate Editor of the *American Journal of Cardiology* and receives research support from the National Institutes of Health (Bethesda, MD), Evalve (Menlo Park, CA), GE (Milwaukee, WI), and Amersham (Amersham, UK). Harry Rakowski chairs the Data Safety Monitoring Board for Medtronic, Inc (Minneapolis, MN). Neil J. Weissman receives research/grant support from ATS Medical, Inc (Minneapolis, MN), Sorin/Carbomedics (Milan, Italy), Edwards Lifesciences (Irvine, CA), St Jude Medical (St Paul, MN), MitralSolutions, Inc (Fort Lauderdale, FL), Arbor Surgical Technologies (Sunnyvale, CA), Evalve (Menlo Park, CA) Mitralign, Inc (Tewksbury, MA), Medispec (Germantown, MD), and Direct Flow Medical, Inc (Santa Rosa, CA). William A. Zoghbi, John B. Chambers, Jean G. Dumesnil, John S. Gottdiener, Bijoy K. Khandheria, Robert A. Levine, Gerald Ross Marx, Fletcher A. Miller, Jr, Satoshi Nakatani, Miguel A. Quiñones, L. Leonardo Rodriguez, Madhav Swaminathan, Alan D. Waggoner, and Miguel Zabalgoitia all reported that they have no actual or potential conflicts of interest in relation to this program.

**Conflict of Interest:**

This activity has been peer reviewed by a nonbiased member of the ASE ACCME/CME committee. No indication of an actual or potential bias in relation to the author disclosures was determined.

**Estimated Time to Complete This Activity:** 1 hour

**TABLE OF CONTENTS**

I. Introduction	976
II. General Considerations With Prosthetic Valves	977
A. Types of Prosthetic Valves	977
B. Evaluation of Prosthetic Valves With Echocardiography and Doppler:	
General Recommendations	977
1. Clinical Data	978
2. Echocardiographic Imaging	978
3. Doppler Echocardiography	979
a. Determination of Gradients Across Prosthetic Valves	979
b. EOA	980
c. Pressure Recovery: Hemodynamic Conditions and Clinical Implications	980
d. PPM	981
e. Doppler Recordings and Measurements Based on Prosthetic Valve Position	981
f. Physiologic Regurgitation	982
g. Pathologic Prosthetic Regurgitation	982
C. Considerations for Intraoperative Patients	982
D. Complications of Prosthetic Valves	983
1. General Considerations: Early Versus Late Complications	983
a. Early Complications	983
b. Late Complications	983
2. Endocarditis	983
3. Prosthetic Valve Thrombosis Versus Pannus	984
E. Stress Echocardiography in Evaluating Prosthetic Valve Function	984
1. Prosthetic Aortic Valves	984
2. Prosthetic Mitral Valves	985
F. Other Techniques for Assessing Replacement Heart Valves	986
1. Cinefluoroscopy	986
2. CT	986
3. Cardiac Catheterization	986
G. Postoperative Evaluation and Follow-Up Studies	986
III. Evaluation of Prosthetic Aortic Valves	986
A. Prosthetic Aortic Valve Function and Stenosis	986
1. Imaging Considerations	986
2. Doppler Parameters of Prosthetic Aortic Valve Function	986
a. Velocity and Gradients	986
b. EOA	987
c. DVI	987
3. Diagnosis of Prosthetic Aortic Valve Stenosis	987
B. Prosthetic Aortic Valve Regurgitation	989
1. Imaging Considerations	989
2. Doppler Evaluation of Severity of Prosthetic AR	989
a. Color Doppler	989
b. Spectral Doppler	990
3. Role of TEE in Prosthetic AR	991
4. An Integrative Approach in Evaluating Prosthetic AR	991
IV. Evaluation of Prosthetic Mitral Valves	991
A. Prosthetic Mitral Valve Function and Stenosis	991
1. Imaging Considerations	991
a. Parasternal Views	991
b. Apical Views	992
2. Doppler Parameters of Prosthetic Mitral Valve Function	992
a. Peak Early Mitral Velocity	992
b. Mean Gradient	993
c. Pressure Half-Time	993
d. EOA	994
e. DVI	995
3. Diagnosis of Prosthetic Mitral Valve Stenosis	995
B. Prosthetic Mitral Valve Regurgitation	996
1. Imaging Considerations	996
2. Role of TEE	996
3. Assessment of Severity of Prosthetic MR	996
V. Evaluation of Prosthetic Pulmonary Valves	996
A. Prosthetic Pulmonary Valve Function	996
1. Imaging Considerations	996
2. Evaluation of Pulmonary Valve Function	998
B. Prosthetic Pulmonary Valve Regurgitation	998
VI. Evaluation of Prosthetic Tricuspid Valves	998
A. Prosthetic Tricuspid Valve Function	998
1. Imaging Considerations	998
2. Doppler Parameters of Tricuspid Prosthetic Valve Function	999
3. Diagnosis of Prosthetic Tricuspid Valve Stenosis	999
B. Prosthetic TR	1000
1. Imaging Considerations	1000
2. Doppler Parameters of Tricuspid Prosthetic Valve Regurgitation	1000
3. TEE for Prosthetic Tricuspid Valves	1001
VII. Echocardiographic Evaluation of Prosthetic Valves in the Pediatric Population	1002
A. Prosthetic Valves Are Uncommon in Pediatrics	1002
B. Aspects of Pediatric Congenital Heart Disease Alter the Standard Approach to Echocardiographic Prosthetic Valve Evaluation	1002
C. Importance of PPM in Pediatrics	1003
D. Potential Pitfalls in the Measurement of Prosthetic Valve EOA in Pediatrics	1004
E. Evaluation of Corresponding Atrial and Ventricular Size and Function	1004
F. The Need for More Research in the Pediatric Population	1004
VIII. Conclusions and Future Directions	1004
Appendix A: Normal Doppler Echocardiographic Values for Prosthetic Aortic Valves	1010
Appendix B: Normal Doppler Echocardiographic Values for Prosthetic Mitral Valves	1013

**I. INTRODUCTION**

In patients with significant valvular stenosis or regurgitation, an intervention on the valve with repair, valvuloplasty, or valve replacement is ultimately inevitable. Although valve repair is now frequently performed, especially for mitral regurgitation (MR) and tricuspid regurgitation (TR), valve replacement remains common, particularly in adults. This enlarging cohort may be difficult to assess. Symptoms may be nonspecific, making it difficult to differentiate the effects of prosthetic valve dysfunction from ventricular dysfunction, pulmonary hypertension, the pathology of the remaining native valves, or noncardiac conditions. Although physical examination can alert clinicians to the presence of significant prosthetic valve dysfunction, diagnostic methods are often needed to assess the function of the prosthesis. Echocardiography with Doppler is the method of choice for the

noninvasive evaluation of prosthetic valve function. This document offers a review of echocardiographic and Doppler techniques used in the assessment of prosthetic valves and provides recommendations and general guidelines for the evaluation of prosthetic valve function on the basis of the scientific literature and the consensus of an international panel of experts. Issues of medical management and considerations for reoperation on valvular complications are beyond the scope of the current recommendations and have been recently addressed.<sup>1</sup>

Echocardiography of prosthetic heart valves is more demanding, both to perform and to interpret, compared with the assessment of native valves. By their design, almost all replacement valves are obstructive compared with normal native valves. The degree of obstruction varies with the type and size of the valve. Thus, it may be difficult to differentiate obstructive hemodynamics due to valve design from those of mild obstruction observed with pathologic changes and from prosthesis-patient mismatch (PPM). Most mechanical valves and many biologic valves are associated with trivial or mild transprosthetic regurgitation. The pattern of this "physiologic" regurgitation varies with the design of the replacement valve. Last, because of shielding and artifacts, insonation of the valve and particularly of regurgitant jets associated with the valve may be difficult. A full transthoracic echocardiographic study requires multiple angulations of the probe and the use of off-axis views. On rare occasions, intermittent obstruction may be suspected, and prolonged Doppler examination may then be required for diagnosis. Transesophageal echocardiography (TEE) is more likely to be needed than for native valves for the evaluation of prosthetic valvular structure and associated complications, including regurgitation, especially in the mitral position.

## **II. GENERAL CONSIDERATIONS WITH PROSTHETIC VALVES**

### **A. Types of Prosthetic Valves**

Over the past 40 years, a large variety of prosthetic valves have been developed with the aim of improving hemodynamic function, increasing durability, and reducing complications. Nevertheless, there is no ideal valve, and all prosthetic valves are prone to dysfunction. The valve types now implanted include bileaflet and tilting disc mechanical valves, stented porcine and pericardial xenografts, stentless porcine xenografts, cadaveric homografts, and autografts (Ross procedure). Various types of currently used prosthetic valves in the aortic and mitral positions are listed in Appendices A and B. [Figures 1 and 2](#) depict examples of mechanical and bioprosthetic valves and their echocardiographic images, respectively. In patients with aortic root disease, composite grafts may be required to replace the aortic valve and root, usually necessitating coronary reimplantation. Recently, successful percutaneous aortic and pulmonary valve replacements have been accomplished.

Prosthetic valves are broadly grouped as biologic or mechanical ([Table 1](#)).<sup>2</sup> The most frequently implanted biologic valve is a stented xenograft. These are composed of fabric-covered polymer or wire stents. The valve may be an entire porcine valve or a composite from 2 or 3 individual pigs. The cusps of stented pericardial xenografts are made from pericardium using a template and sewn inside or outside of the stent posts. Usually, the pericardium is bovine, but pericardium of other species has also been used. Xenografts also differ in the method of preservation of the valve cusps, the use of anticalcification regimens, and the composition and design of the stents and sewing rings.

Stentless xenograft graft valves usually consist of a preparation of porcine aorta. The aorta may be relatively long (Medtronic Freestyle; Medtronic, Inc, Minneapolis, MN) or may be sculpted to fit under the coronary arteries (St Jude Medical Toronto; St Jude Medical, St Paul Minnesota). Some are tricomposite (CryoLife O'Brien, CryoLife, Inc, Kennesaw, GA; BioCor, LLC, Yardley, PA) or made from bovine pericardium (Sorin Freedom; Sorin Group, Milan, Italy). Homograft valves consist of cryopreserved human aortic or, less commonly, pulmonary valves. Most are prepared in tissue banks, although a small number are produced by commercial companies (eg, CryoLife). Stentless valves were introduced to increase the effective orifice area (EOA). It was also hoped that stresses on the cusps might be lessened, leading to better durability and less thrombosis.

Currently, the most frequently implanted mechanical valves are the bileaflet valves. The various designs differ in the composition and purity of the pyrolytic carbon, the shape and opening angle of the leaflets, the design of the pivots, the size and shape of the housing, and the design of the sewing ring. Single tilting disc valves are also frequently used, whereas the Starr-Edwards caged-ball valve is rarely used nowadays but, because of its durability, will continue to be encountered.

Usually, the reported size of a prosthesis refers to the outer diameter of the valve ring, in millimeters. Comparison of the different valve types is difficult, however, because of major variations in sizing convention.<sup>3,4</sup> This means that for a given patient's tissue annulus, there may be major differences in the labeled size. In a study comparing valve size as stated by the manufacturer against a modeled patient tissue annulus provided by machined polypropylene blocks, the patient "tissue annulus" diameter ranged from 3.5 mm smaller to 3.0 mm larger than the labeled size.<sup>4</sup>

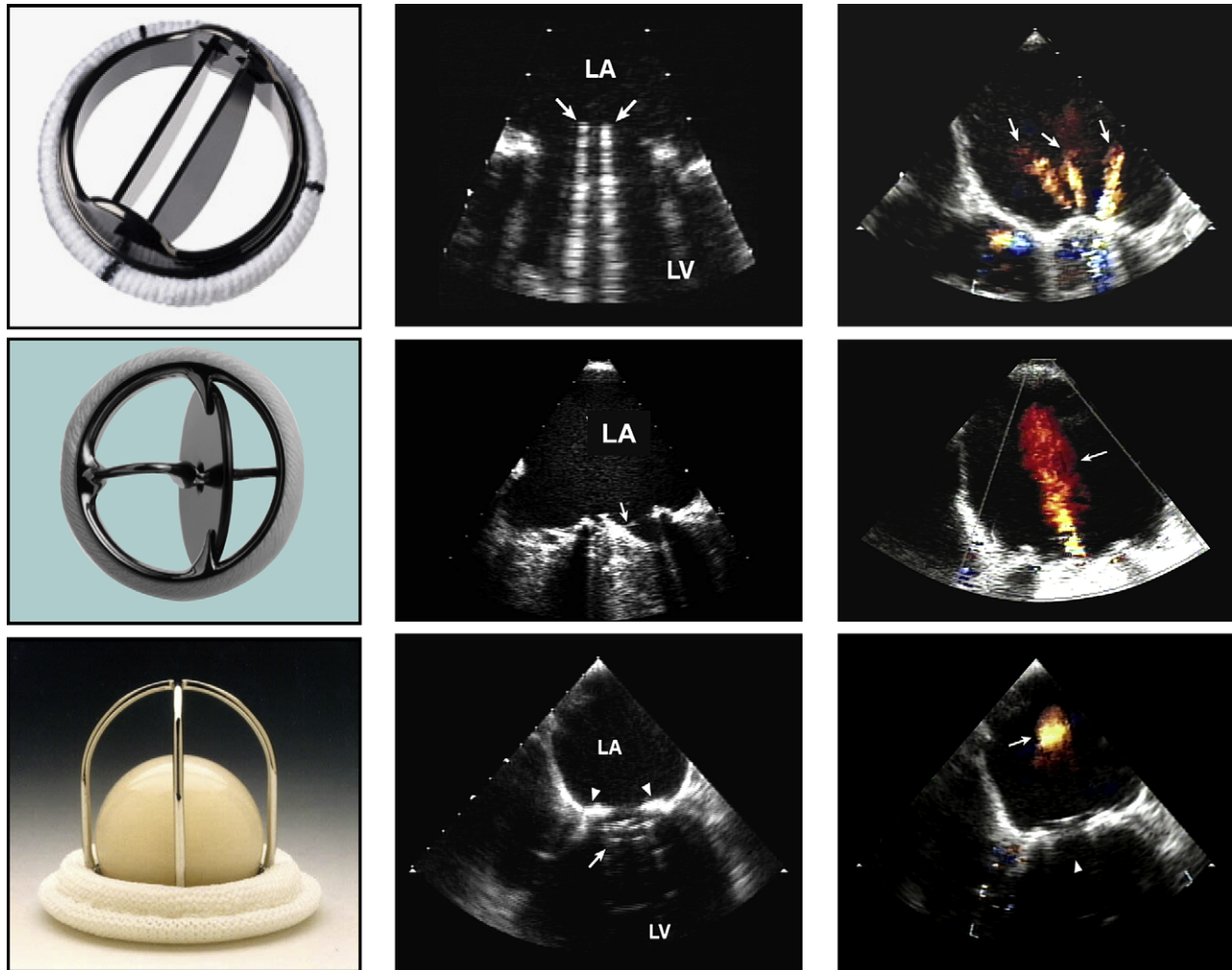
The various valve types can differ also by their implantation position relative to the valve annulus. This is mainly in the aortic site. Valve implantation can be intra-annular, partially supra-annular, or wholly supra-annular. The supra-annular position is designed to lift as much of the replacement valve above the annulus to maximize the orifice area available for flow. The maximum label size implantable may then be limited by the diameter of the aortic root or the position of the coronary ostia.

Percutaneous valve implantation is an emerging technique whose feasibility has already been demonstrated.<sup>5-7</sup> Clinical trials evaluating safety and durability are currently in progress. Percutaneous valves have been implanted in the pulmonary and aortic positions.<sup>5-7</sup> The basic concept is of a tissue valve mounted on a balloon or self-expandable stent. Preliminary experience suggests that echocardiography will be a valuable tool for guiding the procedure and for the evaluation of gradients and residual aortic regurgitation (AR).<sup>8</sup> Normal values for velocities and gradients are available in a small number of patients, but low gradients should be expected.<sup>7,8</sup>

In select older high-risk patients, particularly those with prior coronary artery bypass grafting and severely calcific aortas in whom aortic cross-clamping would pose undue technical difficulty and risk, an aortic valve bypass (apicoaortic conduit) may be performed. This operation interposes a fabric conduit containing either a bioprosthetic or mechanical valve between the left ventricular (LV) apex and descending thoracic aorta.<sup>9</sup> Postoperative evaluation focuses on evaluation of the apical cannula for absence of thrombus and adequate flow.

### **B. Evaluation of Prosthetic Valves With Echocardiography and Doppler: General Recommendations**

A comprehensive evaluation is needed for the optimal assessment of prosthetic valve function. This includes obtaining pertinent clinical information in addition to echocardiography and Doppler evaluation. A



**Figure 1** Examples of bileaflet, single-leaflet, and caged-ball mechanical valves and their transesophageal echocardiographic characteristics taken in the mitral position in diastole (*middle*) and in systole (*right*). The *arrows* in diastole point to the occluder mechanism of the valve and in systole to the characteristic physiologic regurgitation observed with each valve. Videos 1 to 6 show the motion and color flow patterns seen with these valves. [View video clips online.](#)

comparison with a baseline study or serial postoperative Doppler echocardiographic studies is often helpful, particularly when the function of the valve is in question (Table 2).

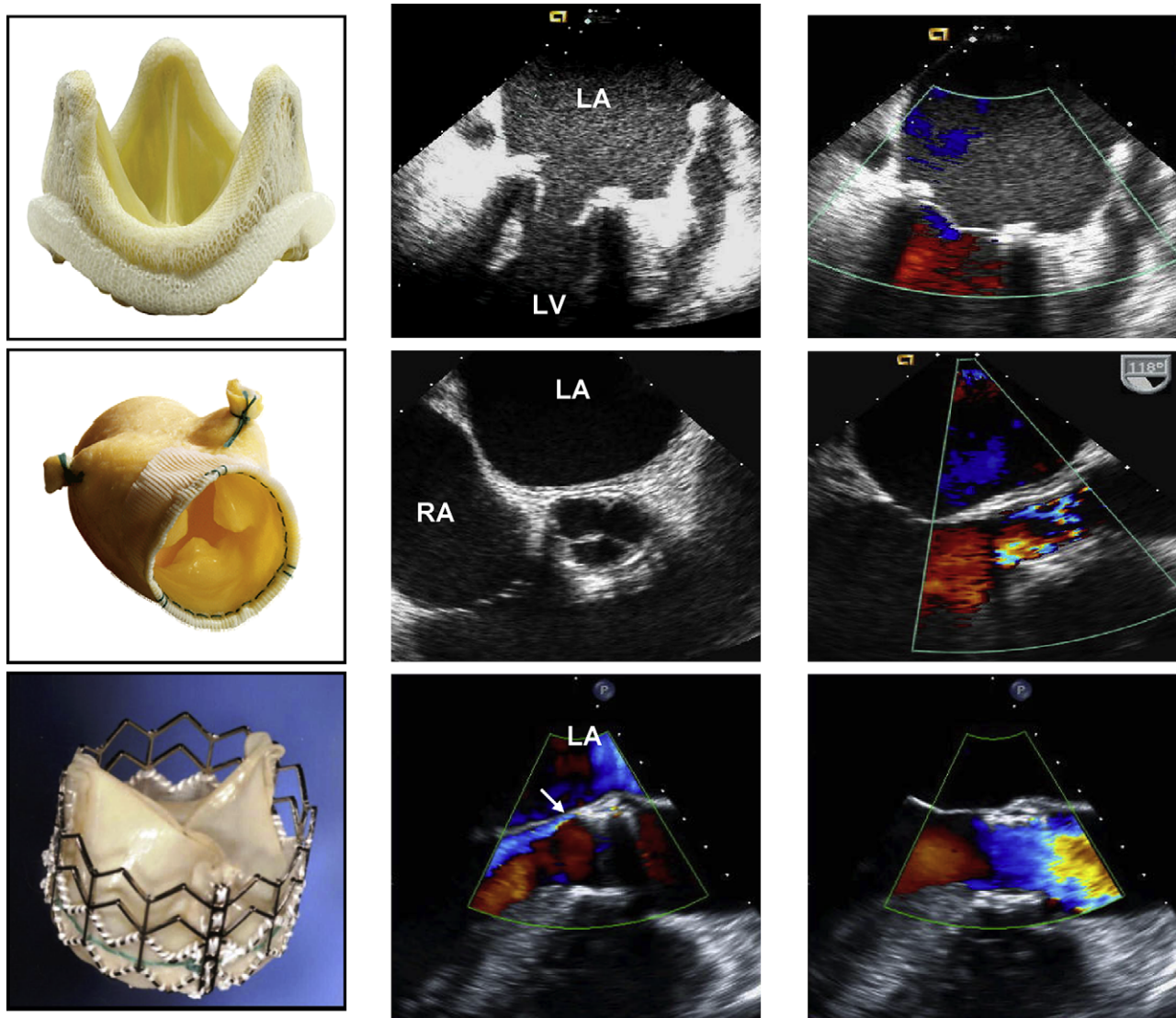
**1. Clinical Data.** The reason for the echocardiographic study and the patient's symptoms should be clearly documented. Furthermore, because Doppler findings and interpretation depend on the type and size of the replacement valve, this information and the date of surgery should be incorporated in the report when available, as this can be used in subsequent studies. Blood pressure and heart rate should be measured. The heart rate of the cardiac cycles used for Doppler measurements is particularly important in mitral and tricuspid prosthetic valves, because the mean gradient is dependent on the diastolic filling period. Finally, the patient's height, weight, and body surface area should be recorded to assess whether PPM is present and to interpret cardiac chamber size.

**2. Echocardiographic Imaging.** The echocardiographic assessment of patients with prosthetic valves includes standardized measurement and evaluation of the size of cardiac chambers, LV wall thickness and mass, and indices of LV systolic and diastolic function

per guidelines of the ASE.<sup>10</sup> In patients with aortic prostheses, measurements of the aortic root and ascending aorta are recommended. Valves should be imaged from multiple views, with particular attention to the following:

- the opening and closing motion of the moving parts of the prosthesis (leaflets for bioprosthesis and occluders for mechanical prostheses);
- the presence of leaflet calcifications or abnormal echo density attached to the sewing ring, occluder, leaflets, stents, or cage; and
- the appearance of the sewing ring, including careful inspection for regions of separation from the native annulus and for abnormal rocking motion during the cardiac cycle.

In general, magnification of real-time images is necessary for better visualization of the leaflets or occluder mechanism. Mild thickening is often the first sign of primary failure of a biologic valve and is a signal to follow the patient more carefully.<sup>11</sup> Occluder motion of a mechanical valve may not be well visualized by transthoracic echocardiography (TTE) because of artifact and reverberations. Nevertheless, optimal 2-dimensional (2D) echocardiographic visualization of occluder motion in tilting disc valves in the mitral or tricuspid position frequently necessitates incremental rotation of the imaging plane



**Figure 2** Examples of stented, stentless, and percutaneous biologic valves and their echocardiographic features in diastole (*middle*) and in systole (*right*) as seen by TEE. The stentless valve is inserted by the root inclusion technique. Mild perivalvular AR in the percutaneous valve is shown by *arrow*. The percutaneous biologic valve is currently for investigational use only. Videos 7 to 10 show the valve motion and color Doppler flow pattern of these valves. [View video clips online.](#)

from apical views until the occluder motion is seen. Rocking motion of a replacement valve is almost invariably a sign of a large dehiscence in the aortic position.<sup>12</sup> For valves in the mitral position, however, retention of the posterior or both the anterior and posterior native leaflets can allow increased mobility of a normal prosthesis. This situation can usually be differentiated from a dehiscence by the absence of a regurgitant jet. A few microcavitations, detected as microbubbles, are often seen within the LV cavity in the presence of mechanical valves; these are of doubtful clinical significance. The aortic root may be thickened as a result of hematoma and edema after the insertion of a stentless valve as an inclusion inside the aortic root.<sup>13,14</sup> This appearance, which can be initially mistaken for an aortic root abscess, usually resolves over 3 to 6 months. This entity can be corroborated on review of the intraoperative or early postoperative study, if available. Last, in patients with or without histories of infective endocarditis, a search for the presence of abscess formation in the region of the prosthetic valve annulus or sewing ring should be undertaken. Most

of the above structural abnormalities however are usually better delineated with TEE.

**3. Doppler Echocardiography.** The principles of interrogation and recording of flow velocity through prosthetic valves are similar to those used in evaluating native valve stenosis or regurgitation.<sup>15,16</sup> This includes pulsed-wave (PW) and continuous-wave (CW) Doppler as well as color Doppler, using several windows for optimal recording and minimizing angulation between the Doppler beam and flow direction.

**a. Determination of Gradients Across Prosthetic Valves.** Blood velocity across a prosthetic valve is dependent on several factors, including flow and valve size and type. The simplified Bernoulli equation has been the key to the noninvasive calculation of pressure gradients across all cardiac valves, including prosthetic valves,<sup>17</sup> whereby pressure gradient is derived as  $4 \times V^2$ , where  $V$  is the

**Table 1** Types of prosthetic heart valves

Biologic
Stented
Porcine xenograft
Pericardial xenograft
Stentless
Porcine xenograft
Pericardial xenograft
Homograft (allograft)
Autograft
Percutaneous
Mechanical
Bileaflet
Single tilting disc
Caged-ball

velocity of the jet in meters per second. In patients with aortic prostheses and high cardiac output or narrow LV outflow (LVO), the velocity proximal to the prosthesis may be elevated and therefore not negligible (proximal velocity > 1.5 m/s). In these situations, estimation of the pressure gradient is more accurately determined by considering the velocity proximal to the prosthesis as  $P = 4(V_2^2 - V_1^2)$ . Pressure gradients derived with the simplified Bernoulli equation have correlated well with hemodynamically measured gradients. In bileaflet prostheses and caged-ball valves, however, overestimation of the gradient may occur, particularly with smaller valves and high cardiac output (see below).<sup>18-21</sup>

b. EOA. The EOA of a prosthesis by the continuity equation is a better index of valve function than gradient alone. This is calculated as

$$EOA = \text{stroke volume} / \text{VTI}_{\text{P-V}}$$

where  $\text{VTI}_{\text{P-V}}$  is the velocity-time integral through the prosthesis determined by CW Doppler. Stroke volume is usually derived as cross-sectional area just proximal to the prosthesis (in aortic or pulmonary valves) multiplied by the VTI of flow by PW Doppler at that site. Using the label size of the prosthetic valve to calculate the cross-sectional area of the annulus is not valid because of significant discrepancy between these measurements. In prosthetic mitral valves, stroke volume calculated at the aortic annulus or pulmonary annulus may be used, provided no significant regurgitation exists. In prosthetic aortic valves, a simplification of the continuity equation is the Doppler velocity index (DVI), the ratio of velocity proximal to the valve, to the velocity through the valve.<sup>22</sup> This index does not rely on measurement of the LVO tract. Conceivably, it may also be applied to prosthetic pulmonary valves, but validation is needed.

c. Pressure Recovery: Hemodynamic Conditions and Clinical Implications. In prosthetic valves, the phenomenon of pressure recovery can occur in two regions: (1) downstream of a valve and (2) within some prosthetic valves, typically bileaflet or caged-ball valves.<sup>18-21,23-31</sup>

In the first scenario (Figure 3, left), as flow expands into the wider lumen beyond a valve, velocity and kinetic energy will decrease and pressure will be recovered. The pressure gradient measured directly by catheter therefore decreases as the catheter port is moved downstream from the prosthetic orifice and will generally be smaller than the gradient estimated from maximal CW Doppler velocity at the vena contracta: the smallest area occupied by flow. The magnitude of this phenomenon is generally small, except in cases in which the aorta is <3 cm in diameter, an infrequent finding in adults.

**Table 2** Essential parameters in the comprehensive evaluation of prosthetic valve function

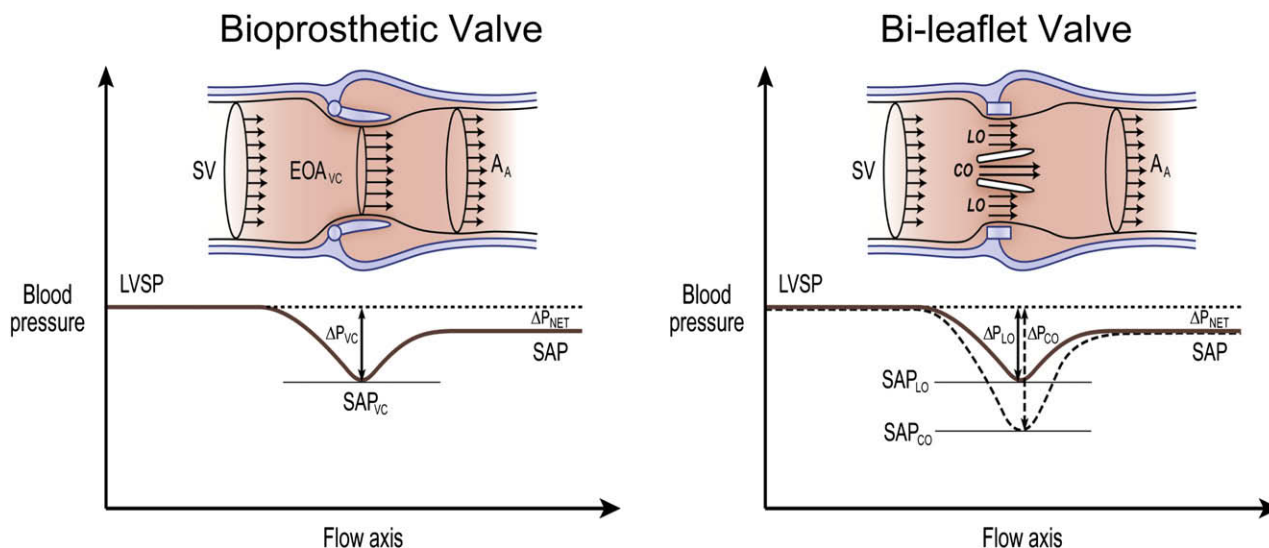
	Parameter
Clinical information	Date of valve replacement Type and size of the prosthetic valve Height, weight, body surface area Symptoms and related clinical findings Blood pressure and heart rate Motion of leaflets or occluder
Imaging of the valve	Presence of calcification on the leaflets or abnormal echo densities on the various components of the prosthesis Valve sewing ring integrity and motion
Doppler echocardiography of the valve	Contour of the jet velocity signal Peak velocity and gradient Mean pressure gradient VTI of the jet DVI Pressure half-time in MV and TV. EOA* Presence, location, and severity of regurgitation†
Other echocardiographic data	LV and RV size, function, and hypertrophy LA and right atrial size Concomitant valvular disease Estimation of pulmonary artery pressure
Previous postoperative studies, when available	Comparison of above parameters is particularly helpful in suspected prosthetic valvular dysfunction

MV, Mitral valve; TV, tricuspid valve.

\*EOA using the continuity equation; needs to be compared with normal Doppler values of the valve type and size.

†Transthoracic Doppler is less sensitive to detection of valvular regurgitation in mitral and tricuspid prosthesis; TEE is frequently needed for a more definitive assessment.

In the case of mechanical bileaflet prostheses (Figure 3, right), the particular design of the valve may cause a separate phenomenon of pressure recovery at the level of the valve. This is not seen in mono-leaflet prostheses or bioprostheses but may be observed in caged-ball prostheses.<sup>19</sup> The smaller central orifice in bileaflet valves may give rise to a high-velocity jet that corresponds to a localized pressure drop that is largely recovered once the central flow reunites with flows originating from the two lateral orifices (Figure 3, right).<sup>18,19</sup> CW Doppler recording often includes this high-velocity jet, which leads to overestimation of gradients and thus underestimation of EOA compared with the invasive hemodynamic standard, particularly in small prostheses and in high flow states. Differentiation of central from lateral orifice jets by Doppler is usually not feasible with TTE but is possible with TEE in prosthetic mitral valves. These effects of pressure recovery usually do not confer a significant problem in assessing valvular dysfunction, because the reported normal Doppler values for bileaflet and caged-ball valves (Appendices A and B) already incorporate this phenomenon, with which individual patient values are compared.<sup>32</sup> However, in situations in which bileaflet valves are very small (19 mm) and accompanied by high flow, differentiation



**Figure 3** Schematic representation of velocity and pressure changes from the LVO tract to the ascending aorta ( $A_A$ ) in the presence of a stented bioprosthesis and a bileaflet mechanical valve illustrating the phenomenon of pressure recovery. Because of pressure recovery, velocities are lower and systolic arterial pressure (SAP) is higher at the distal aorta than at the level of the vena contracta (VC). This is further exaggerated in the case of a bileaflet valve, in which the velocity is higher in the central orifice (CO) and thus pressure drop is higher at that level. Doppler gradients are estimated from maximal velocity at the level of the vena contracta and represent the maximal pressure drop, whereas invasive estimation of gradients usually reflect net pressure difference ( $\Delta P$ ) between LV systolic pressure (LVSP) and ascending aorta. LO, Lateral orifice; SV, stroke volume in LVO.

from normal may be difficult and requires evaluation of valve motion and structure using TEE, fluoroscopy, and/or computed tomography (CT).

d. PPM. The physiologic relationship between flow, valve area, and gradient is illustrated by the equation  $\text{gradient} = Q^2 / (K \times \text{EOA}^2)$ , where  $Q$  is flow and  $K$  is a constant. For gradients to remain low, the EOA must be proportionate to the flow requirements of the individual, which at rest are largely determined by body size. PPM occurs when the EOA of the prosthesis is too small in relation to the patient's body size, resulting in abnormally high postoperative gradients.<sup>33-36</sup>

The parameter used to characterize PPM is EOA indexed to the patient's body surface area. Although the principles underlying PPM theoretically apply to all valve positions, most studies have focused on the aortic valve. Gradients increase exponentially when the indexed EOA is  $\leq 0.8$  to  $0.9 \text{ cm}^2/\text{m}^2$ .<sup>33,35,37</sup> On the basis of this relationship, PPM is considered to be hemodynamically insignificant if the indexed EOA is  $>0.85 \text{ cm}^2/\text{m}^2$ , moderate if between  $0.65$  and  $0.85 \text{ cm}^2/\text{m}^2$ , and severe if  $<0.65 \text{ cm}^2/\text{m}^2$ .<sup>36</sup> Such categorization is important because the impact of PPM on clinical outcomes increases with severity.<sup>38,39</sup> The reported prevalence of moderate PPM varies between 20% and 70%, whereas that of severe PPM is between 2% and 11%.<sup>36,38,40</sup> It should be emphasized that the indexed EOA, not the size or geometric specifications of the prosthesis, is the only parameter to be consistently related to postoperative gradients and/or adverse clinical outcomes.<sup>41-44</sup>

The main adverse clinical outcome ascribed to PPM is reduced short-term and long-term survival, particularly if associated with LV dysfunction.<sup>38,45,46</sup> There are some reports of lesser regression of LV hypertrophy,<sup>40</sup> increased incidence of late cardiac events,<sup>39,46</sup> and less improvement in functional class,<sup>47</sup> although other studies have found little effect. PPM can largely be avoided<sup>36,43,44,48,49</sup> by the calculation of the projected indexed EOA of the prosthesis to

be implanted. If PPM is anticipated, choosing an alternative prosthesis or considering aortic root enlargement surgery is advised.

PPM has also been described in the mitral position.<sup>50</sup> It has been suggested that the indexed EOA of mitral prostheses should ideally be no less than  $1.2$  to  $1.3 \text{ cm}^2/\text{m}^2$  to avoid abnormally high postoperative gradients.<sup>34,35</sup> Depending on the study,<sup>51-53</sup> the reported prevalence for mitral PPM varies between 39% and 71% and was shown to be associated with persisting pulmonary hypertension<sup>52</sup> and decreased long-term survival.<sup>51,53</sup>

Recent data suggest that PPM may not have similar detrimental effects in obese patients (body mass index  $> 30 \text{ kg}/\text{m}^2$ ) compared with nonobese patients.<sup>54</sup> For similar body surface areas, obese patients tend to have lower cardiac output requirements. Future studies are needed to determine if it would be more appropriate to index the EOA for fat-free mass rather than body surface area in obese patients.

e. Doppler Recordings and Measurements Based on Prosthetic Valve Position. For the aortic position, the measurements needed are peak velocity, mean gradient, VTI, DVI, and EOA by the continuity equation. For serial studies, it is reasonable to use the DVI (see below under "Prosthetic Aortic Valves") because this avoids measuring the LVO tract diameter. For the pulmonary position, the measurements needed are those of peak velocity and derived mean pressure difference. Although EOA and DVI could be calculated for a prosthetic pulmonary valve, little experience exists with these parameters.

In the mitral and tricuspid positions, the measurements needed are peak velocity, mean pressure gradient, VTI, and pressure half-time. Heart rate reporting is essential. It is not appropriate to use the pressure half-time formula ( $220/\text{pressure half-time}$ ) to estimate orifice area in prosthetic valves. This is valid only for moderate or severe stenoses with orifice areas  $< 1.5 \text{ cm}^2$ . For larger valve areas, the pressure half-time reflects atrial and LV compliance characteristics and loading conditions and has no relation to valve area.<sup>34,55</sup>

Doppler recordings should be performed at a sweep speed of 100 mm/s. Measurements should be taken over 1 to 3 cycles in sinus rhythm. In atrial fibrillation, Doppler measurements should be performed when possible during periods of physiologic heart rate (65-85 beats/min). Averaging from 5 to 15 beats in atrial fibrillation has been suggested but is cumbersome and may still give an unrepresentative result, because cycle lengths may vary substantially. In cases in which the derivation of a parameter requires measurements from different cardiac cycles (eg, EOA by the continuity equation, DVI), matching of the respective cycle lengths to within 10% is advised. For prosthetic aortic EOA calculation, the preceding intervals of LVO velocity and prosthetic valve flow should be matched, whereas for mitral valves, the cycle length of mitral inflow should be matched with the preceding interval of LVO velocity, if this is an acceptable site for stroke volume measurement.

**f. Physiologic Regurgitation.** Minor regurgitation is normal in virtually all mechanical valves (Figures 1 and 2). Two types of "physiologic" regurgitation may be seen: a closing volume (a displacement of blood caused by the motion of the occluder) and true trivial or mild regurgitation at the hinges of the occluder. For the Starr-Edwards valve, there is a typical small closing volume and usually little or no true transvalvular regurgitation (Figure 1). The single tilting disc valves have both types of regurgitation, but the pattern may vary: the Bjork-Shiley valve has small jets located just inside the sewing ring, where the closed disc meets the housing, while the Medtronic Hall valve has these same jets plus a single large jet through a central hole in the disc (Figure 1). The bileaflet valves typically have multiple jets located just inside the sewing ring, where the closed leaflets meet the housing, and centrally, where the closed bileaflets meet each other (Figure 1). These "washing jets" are thought to prevent the formation of thrombi at sites of stasis within the housing. The associated regurgitant fraction is directly related to the size of the valve and is also larger at low cardiac outputs. Although the regurgitant fraction is usually no larger than 10% to 15%, the associated color jet can look large, up to 5 cm long (especially in Medtronic Hall valves), but narrow at its origin (Figure 1). In the case of bileaflet valves, they are usually found in formation, two from each pivotal point; sometimes these single pivotal washing jets divide into 2 or 3 separate "plumes" (Figure 1). The jets are invariably low in momentum, so that they are homogeneous in color, with aliasing mostly confined to the base of the jet.

Regurgitation is increasingly reported in normal biologic valves, mainly because of increased sensitivity of current ultrasound machines. Stentless valves, including homografts and autografts, are more likely than stented valves to have minor regurgitant jets. Percutaneous aortic valves may have small central and/or paravalvular regurgitation (Figure 2).

**g. Pathologic Prosthetic Regurgitation.** Pathologic regurgitation is either central or paravalvular. Most pathologic central valvular regurgitation is seen with biologic valves, whereas paravalvular regurgitation is seen with either valve type and is frequently the site of regurgitation in mechanical valves. Localization of paravalvular regurgitation may be difficult and is possible with confidence only if a trail of flow can be visualized around the outside of the sewing ring. This may require the use of multiple transducer positions, including off-axis views. Multiplanar TEE may be necessary, particularly in mitral and tricuspid valves. Although paraprosthetic regurgitation is abnormal, small jets are not uncommon, especially during perioperative examination early after surgery. Immediately following implantation, the prevalence of paravalvular regurgitation ranges between 5% and 20%<sup>56,57</sup>; the majority of these leaks, however, are clinically

and hemodynamically insignificant and, in the absence of endocarditis, have a benign course. There is no evidence that they increase the risk for endocarditis, but on occasion, they may cause hemolytic anemia due to red cell destruction.

Broadly, the same principles and methods used for quantitation of native valvular regurgitation, detailed in a previous document,<sup>16</sup> can be used for prosthetic valves, but are more challenging. Because of shielding and reverberations of the prosthesis, detection of regurgitation with TTE is more difficult for valves in the mitral and tricuspid positions, particularly in mechanical valves (Figure 4). Indirect clues from various Doppler parameters can suggest the presence of significant regurgitation. However, TEE is frequently needed for the diagnosis of prosthetic MR. The frequent eccentricity of regurgitant jets, particularly in mechanical valves, renders the quantitation and assessment of regurgitation in general more difficult or limited. Multiple small normal transprosthetic jets cannot be quantified accurately, but this is not necessary in clinical practice. For paravalvular jets, the proportion of the circumference of the sewing ring occupied by the jet gives an approximate guide to severity. Comparative flow measurements for the determination of regurgitant volume or fraction, which frequently rely on the determination of stroke volume at annular sites, can be used for prosthetic AR and pulmonary regurgitation (PR) (annular measurement not hindered by the prosthesis) but not for prosthetic MR. The availability of real-time 3-dimensional (3D) TEE with Doppler may facilitate the quantitation of prosthetic regurgitation.

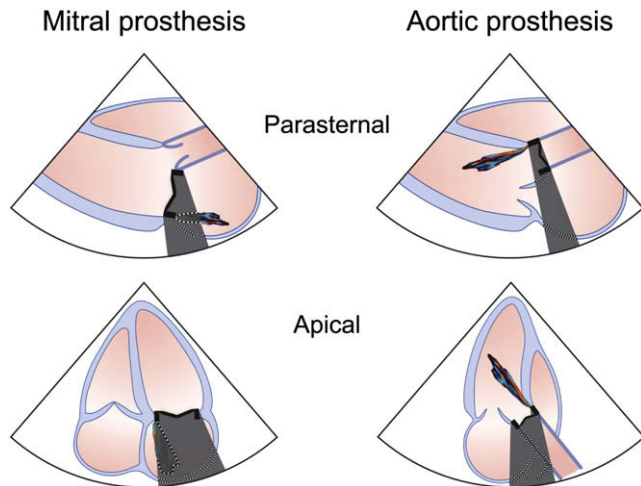
### C. Considerations for Intraoperative Patients

Since its introduction in the early 1970s, intraoperative echocardiography has steadily become an invaluable diagnostic tool for patients undergoing valve surgery. Because of the potential for suboptimal surgical results, the intraoperative detection of prosthetic valve dysfunction is highly desirable. Among the available routes and modalities for imaging, such as TEE and epicardial and epiaortic ultrasound, TEE remains the most widely used. The American Society of Anesthesiologists has recommended intraoperative TEE as a category II indication in patients undergoing valve surgery.<sup>58</sup> Current American College of Cardiology and American Heart Association practice guidelines recommend TEE as a class I indication for patients undergoing valve replacement with stentless xenograft, homograft, or autograft valves.<sup>1</sup>

The comprehensive assessment of prosthetic valves requires advanced echocardiographic training, which must be factored in when the intraoperative use of TEE is considered. Although the criteria for assessment remain similar, intraoperative patients deserve special consideration. The intraoperative environment presents unique challenges. The period prior to cardiopulmonary bypass is usually associated with reduced preload and myocardial depression that accompanies the anesthetized state.<sup>59</sup> Moreover, an open chest, open pericardial cavity, and positive pressure ventilation also influence loading conditions.<sup>60</sup> The postbypass phase, on the other hand, is a labile period during which there are frequent changes in preload and afterload, inotropic and chronotropic drugs may be in effect, and the heart is frequently electrically paced.<sup>61</sup> All of the above factors must be considered during the echocardiographic assessment of prosthetic valve function.

Prosthetic valves may need to be assessed intraoperatively in 3 situations: (1) after the replacement of a diseased native valve, (2) in unrelated cardiac surgery as a part of comprehensive TEE, and (3) prior to redo valve surgery in dysfunctional prosthetic valves. A patient who presents for valve replacement surgery has usually undergone extensive imaging preoperatively, and the decision to replace the valve has already been made. However, in the operating room, the intraoperative echocardiographer can provide valuable feedback





**Figure 4** Effect of mechanical prosthetic valve position and echocardiographic imaging view on shadowing and masking of a regurgitation jet by Doppler. A higher effect from transthoracic imaging is seen on prostheses in the mitral position compared to the aortic position.

to the surgeon regarding the size of the valve annulus to assist with prosthetic valve selection. After cardiopulmonary bypass, the assessment of the newly seated valve is essential. Multiple echocardiographic views are obtained to determine the appropriate movement of valve leaflets, and color flow Doppler should exclude the presence of paravalvular leaks. Intraoperative echocardiography is also important in patients at risk for “geometric mismatch” of the valve and surrounding tissue or annulus, with resultant regurgitation because of the relatively small size of the valve (patients with stentless valves or the Ross procedure). Postoperatively, any regurgitation that is graded moderate or severe would need to be surgically corrected immediately prior to leaving the operating room. Other complications, such as “stuck” mechanical valve leaflets, valve dehiscence, and dysfunction of adjacent valves, may also be detected and require immediate surgical attention. The pressure gradient across a newly seated valve may initially be abnormally high, especially in the aortic position.<sup>62</sup> Several factors could contribute to the finding of an elevated gradient, including high postbypass cardiac output, hemodilution, high subvalvular velocities, and PPM. Regardless of the possible reasons, a high gradient should always prompt the search for mechanical causes of valve obstruction, such as stuck valve leaflets or occlusive thrombus. If echocardiographic assessment demonstrates no apparent mechanical cause, the surgery may proceed as planned and the valve may be interrogated postoperatively. Inappropriately high gradients may also be assessed by alternate imaging modalities, such as epicardial or epi-aortic ultrasound. During the placement of a prosthetic valve in the mitral position, the surgeon may choose a transeptal approach to the left atrium. Postoperatively, the interatrial septum should be evaluated for any residual communication.

In situations in which the insertion of a transesophageal echocardiographic probe is not preferred (eg, esophageal stricture), prosthetic valves may need to be assessed by epicardial or epi-aortic ultrasound. These modalities may also be indicated to interrogate a prosthetic valve to obtain Doppler-derived gradients. Surface echocardiography affords greater flexibility for aligning the Doppler beam with the direction of blood flow. However, appropriate expertise must be available for image acquisition and interpretation.<sup>63</sup>

## D. Complications of Prosthetic Valves

### 1. General Considerations: Early Versus Late Complications.

**a. Early Complications.** Valvular dysfunction after surgery is usually related to technical challenges during surgery or early infection. Paravalvular leak is more frequent after debridement of calcium, repeat valvular surgery, and reconstruction of the aortic or mitral annulus and in older patients. Early leaks are usually mild and may not be detected clinically or by TTE (particularly in the mitral position). PPM and geometric mismatch are increasingly recognized complications of valve replacement (Table 3). Early prosthetic thromboembolism is rare in the absence of a coagulopathy or inadequate anticoagulation. Rarely, the technique of chordal preservation for mitral prostheses may lead to chordal entrapment and obstruction of a mechanical prosthesis. Last, acute endocarditis occurs in <1% of patients and is likely reduced by the common use of perioperative antibiotics.

**b. Late Complications.** The incidence and nature of late dysfunction varies more with the type of prosthesis used, its durability and thrombogenicity, as well as patient factors such as the risk for endocarditis (Table 3). Thromboembolism is determined by the type of heart valve as well as by patient-related factors (LV function, left atrial [LA] size, presence of atrial fibrillation). Mechanical valves are associated with a significant incidence of thromboembolic complications, though critical valve thrombosis is uncommon. The cause is usually inadequate anticoagulation. Both mechanical and tissue valves are also at risk for interaction between the prosthesis and host to create fibrous ingrowth or pannus, which can lead to progressive obstruction. Rizzoli et al<sup>64</sup> followed 2680 patients who received  $\geq 1$  mechanical prosthesis for the development of complications requiring reoperation. Risk increased from the aortic to mitral to double-valve implants. Reoperation for prosthetic valve malfunction was required in 251 patients and was due to dehiscence in 133, pannus in 48 (a linearized rate of 0.24%/patient-year), and thrombosis in 29 (a linearized rate of 0.15%/patient-year).<sup>64</sup> Obstruction of stentless or autograft valves due to thrombosis is rare, and pannus is much less frequent.

Valve degeneration leading to stenosis and/or regurgitation remains the most frequent complication of biologic valves, despite advances in valve design that have led to significant improvement in durability. For example, the Carpentier-Edwards pericardial valve (Edwards Lifesciences, Inc, Irvine, CA), introduced in 1981, has had greater success, with a freedom from structural valve failure in the mitral position that ranges from 69% to 85% at 10 years in a patient population with a mean age of 60 to 70 years.<sup>65</sup> Better results are obtained in the aortic position and worse results in younger patients or in those with renal failure who are more prone to leaflet calcification. Aortic homografts appear to have increased longevity, especially in younger patients, compared with stented valves.<sup>66</sup>

Patients with composite aortic valve and root replacement have the same type of complications as the type of valve used within the conduit and in addition may suffer from pseudoaneurysm or dehiscence at the coronary artery buttons and/or at the annular anastomosis.<sup>67</sup> Although this complication can be suspected from the transthoracic examination, it usually requires transesophageal echocardiographic evaluation. The various complications after valve replacement and their echocardiographic features are beyond the scope of this document and have been recently reviewed.<sup>67</sup>

**2. Endocarditis.** Echocardiography plays a central role in the diagnosis and management of patients with infective endocarditis and should be performed in all cases in which there is a medium or

**Table 3** Early and late complications of prosthetic valves

PPM
Geometric mismatch
Dehiscence
Primary failure
Thrombosis and thromboembolism
Pannus formation
Pseudoaneurysm formation
Endocarditis
Hemolysis

high clinical suspicion or when the patient is severely ill. However, echocardiography is not usually indicated in a stable patient as part of a fever screen until other more common causes of fever are excluded. Vegetations are usually irregularly shaped and can be recognized on echocardiography as independently mobile structures of relatively low echogenicity. Vegetations in the setting of prosthetic valves tend to form in the valve ring area and may spread to the leaflet of the prosthetic valve, stent, or occluder and impair the opening and closing of the valve. Differentiation of vegetations from other masses, such as thrombus, sutures, or pledgets, may be difficult without considering the echocardiographic findings in the context of the clinical presentation. Comparison of findings with those from previous studies is also quite helpful.

Abnormal cavities, produced by either an echo-lucent or an echodense mass, may be seen in the valve ring area. Abscesses are sometimes observed even in cases in which vegetations are absent and may occasionally infiltrate the septum and impair the conduction system. Early after surgery, particularly in stentless valves, edema and hematoma may occur and simulate a walled-off abscess. Progression of an abscess may result in a fistula between the heart chambers. Color Doppler is very useful in these situations for shunt detection. Endocarditis may also lead to suture dehiscence and paravalvular regurgitation in all prosthetic valves and to valve destruction in bioprosthetic valves.

TTE is often limited in assessing prosthetic valve endocarditis and its complications. TEE, on the other hand, demonstrates high sensitivity (86%-94%) and specificity (88%-100%) for the detection of vegetations.<sup>68-70</sup> TEE is also superior to TTE in detecting associated perivalvular abscesses in the posterior but not in the anterior aortic root.<sup>71-73</sup> The reported sensitivity and specificity for the diagnosis of perivalvular abscesses with TTE are 28% and 98%, respectively, and with TEE, 87% and 95%, respectively.<sup>72</sup> TEE is therefore necessary in cases in which infective endocarditis is strongly suspected, even when no significant findings are seen on TTE.<sup>74,75</sup> TEE is also indicated if signs of infection persist or progress despite appropriate antimicrobial treatment, evoking suspected complications such as valve ring abscess or shunt. For the best diagnostic accuracy, a combination of TTE and TEE is needed, because anterior structural abnormalities can be missed by TEE because of shadowing, depending on valve location.<sup>71,74</sup> The negative predictive value of combined TTE and TEE is 95%.<sup>76,77</sup> Thus, although the combined approach is highly accurate in diagnosing endocarditis and its complications, a small percentage of cases can be missed, particularly if clinical suspicion is strong.<sup>77,78</sup> In such cases, a repeat study is recommended after 7 to 10 days.

**3. Prosthetic Valve Thrombosis Versus Pannus.** Prosthetic valve thrombosis is much more common in mechanical than tissue valves. Although thrombus formation is frequently associated with valve obstruction, regurgitation, or embolism, it may be an incidental finding during imaging.<sup>79</sup> Recent history of a systemic embolic event

is associated with the presence of a thrombus<sup>79</sup> or fibrinous-like mobile "strands" that can be detected with TEE.<sup>80,81</sup>

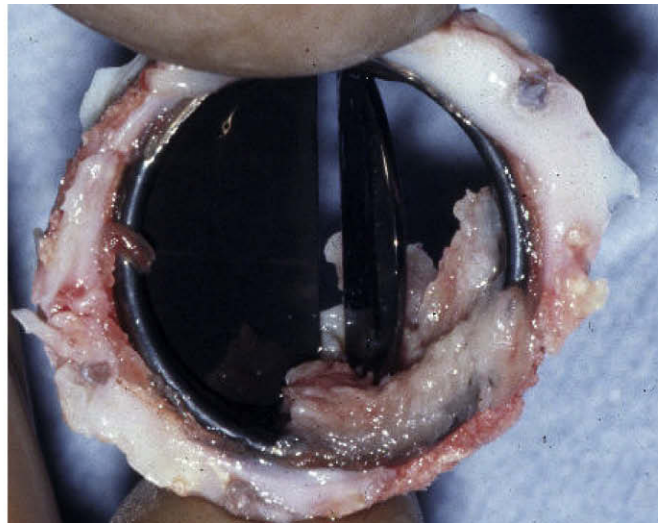
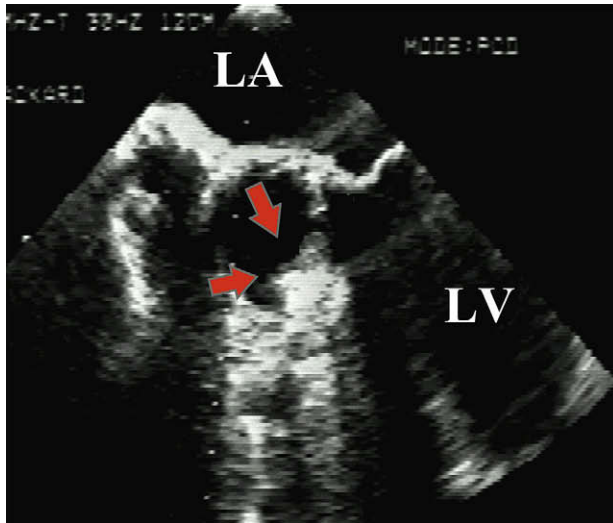
The distinction between thrombus and pannus as the underlying etiology of obstruction is essential if thrombolytic therapy is contemplated. TEE along with clinical parameters can help differentiate the two entities.<sup>82</sup> Thrombi are in general larger and have a soft ultrasound density, similar to that of the myocardium. Specific features for pannus formation include a small dense mass that in 30% of cases may not be distinctly visualized. Detection of abnormal prosthetic valve motion by TEE is more common in valves with thrombus. Pannus formation is more common in the aortic position (Figure 5). Characteristically, thrombi associated with mitral prostheses extend beyond the surgical ring into the left atrium and atrial appendage. Compared with pannus formation, obstruction due to thrombus is associated with a short duration of symptoms and with a history of inadequate anticoagulation (international normalized ratio < 2). The combination of findings of a soft density on the prosthesis and an inadequate international normalized ratio has reported positive and negative predictive values of 87% and 89%, respectively, for thrombus formation.<sup>82</sup>

Thrombus formation may interfere with the mechanism of valve motion and cause significant obstruction that may be catastrophic (Figure 6). Traditionally, these patients underwent redo valve replacement. Recently, fibrinolytic therapy has emerged as an alternative to surgical treatment for obstructed left-sided prosthetic valves and is considered the treatment of choice for tricuspid valve thrombosis.<sup>83-86</sup> If thrombolysis is contemplated, TEE should be performed for diagnosis and risk stratification. A thrombus area on TEE of <0.85 cm<sup>2</sup> confers a lower risk for embolic phenomena or death associated with thrombolysis.<sup>86</sup> Doppler echocardiography is the preferred modality to assess serially the hemodynamic success of thrombolysis.<sup>86,87</sup> It is important to remember that pannus and thrombus may both be present. After thrombolysis that is judged successful on the basis of improved hemodynamics and/or valve motion, it is very important to follow patients with serial clinical and echocardiographic examinations, because residual pannus can lead to rethrombosis of the prosthesis.

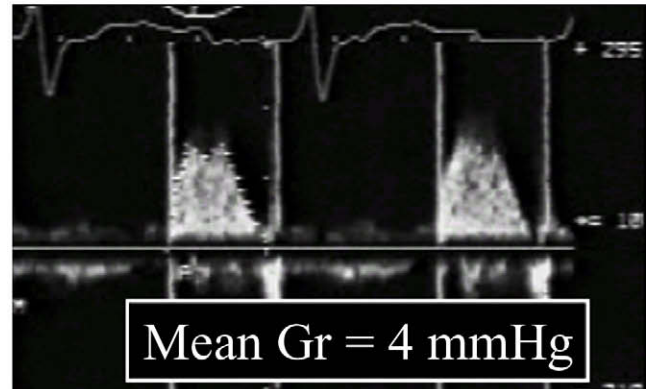
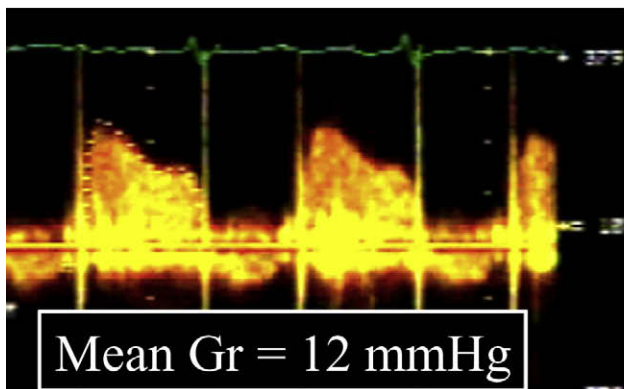
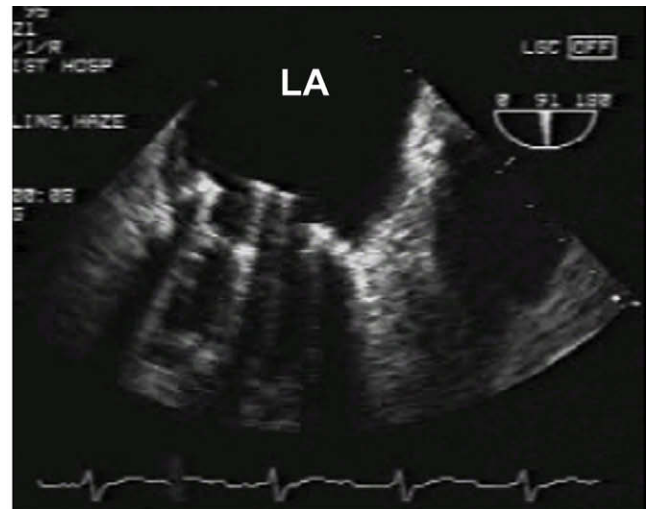
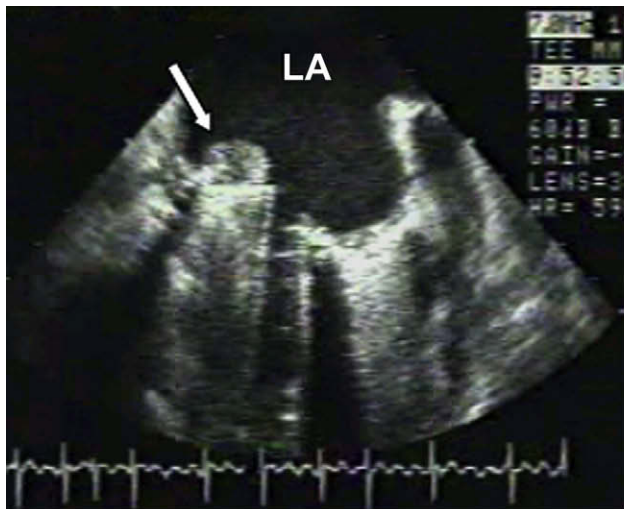
## E. Stress Echocardiography in Evaluating Prosthetic Valve Function

**1. Prosthetic Aortic Valves.** Some patients with symptoms as a result of pathologic obstructions or PPM have equivocal Doppler parameters of prosthetic valve function at rest. Stress echocardiography should be considered in patients with exertional symptoms for which the diagnosis is not clear. The aim is to test for valve dysfunction, coexistent coronary disease, and, on occasion, new or worsening MR. Dobutamine and supine bicycle exercise are most commonly used. Treadmill exercise provides additional information about exercise capacity but is less frequently used because the recording of the valve hemodynamics is after completion of exercise, when the hemodynamics may rapidly return to baseline.

Normally functioning stentless valves open well in systole with a resultant minimal increase in mean pressure gradient from about 6 mm Hg at rest to 9 mm Hg during stress.<sup>88-92</sup> Stented bovine pericardial valves are similar,<sup>93</sup> while porcine valves are relatively more obstructive. In one study, mean pressure difference for the Medtronic intact porcine valve rose from 19 to 28 mm Hg during stress.<sup>91</sup> Comprehensive normal ranges and precise cut points, however, are not available. It is likely that a guide to significant obstruction would be similar to that for native valves, such as a rise in mean gradient >15 mm Hg with stress.<sup>92</sup> In clinical practice, a combination of exact reproduction of symptoms with no



**Figure 5** Pannus formation on a St Jude Medical valve prosthesis in the aortic position as depicted by TEE. The mass is highly echogenic and corresponds to the pathology of the pannus at surgery. The pannus is depicted by the *arrows*. LA, Left atrium; LV, left ventricle.



**Figure 6** Prosthetic St Jude Medical valve thrombosis in the mitral position (*arrow*) obstructing and immobilizing one of the leaflets of the valve. After thrombolysis, leaflet mobility is restored, and the mean gradient (Gr) is significantly decreased. LA, Left atrium.

wall motion abnormality and a large rise in pressure difference is highly suggestive of abnormal valve dynamics.

**2. Prosthetic Mitral Valves.** Exertional dyspnea after mitral valve replacement may be caused by primary valve failure, LV and/or right

ventricular (RV) dysfunction, pulmonary hypertension, or other non-cardiac causes. Stress echocardiography should be considered in patients with exertional symptoms for which the diagnosis is not clear. The aims are to record changes in transmitral velocities and the tricuspid regurgitant signal. Stress testing modalities similar to those for

aortic valves can be used. In the elderly, light exercise around the echocardiography laboratory or using a step stool may be sufficient to elicit the abnormal hemodynamics. No normal ranges or cut points exist, but data from native valves provide a guide. Obstruction or PPM is likely if the mean gradient rises above 18 mm Hg after exercise, even when the resting mean gradient is normal.<sup>94</sup>

## F. Other Techniques for Assessing Replacement Heart Valves

**1. Cinefluoroscopy.** Cinefluoroscopy was the first noninvasive imaging technique to evaluate prosthetic valves. In mechanical prosthetic valves, cinefluoroscopy is easily applied because of the radiopaque base ring and the ball or disc occluder. In tissue valves, however, cinefluoroscopy has limited value.<sup>95-97</sup> Abnormal tilting or rocking of the base ring is indicative of extensive valve dehiscence. Small or moderate dehiscence, however, cannot be diagnosed without cardiac catheterization and dye injection. Impaired excursion or incomplete seating of the moving parts of the prosthesis suggests the presence of tissue in-growth or thrombus. Detection of calcium on the leaflets of a tissue valve is diagnostic of degeneration but does not allow assessment of its hemodynamic impact.<sup>98,99</sup> A serious complication of older models of valve prostheses with dramatic clinical presentation and high mortality was strut fracture with disc embolization. In these cases, cinefluoroscopy or plain-film radiography was the study of choice.<sup>100-103</sup> Modifications in design and construction in the new generation of valves have abolished this problem.

With the advent of TEE, motion as well as structure of prosthetic valves can be assessed, thus providing an advantage over cinefluoroscopy. TEE allows an excellent evaluation of valve motion in mitral and tricuspid prosthetic valves, because of their en face position in relation to the imaging plane. Cinefluoroscopy currently still plays a complementary diagnostic role in evaluating disc mobility of mechanical aortic valves.

**2. CT.** In prosthetic valves, the simple visualization of mobile cusps or occluder, without quantification, can be enough to differentiate PPM from pathology as a cause of unexpectedly high gradients. Case studies have reported successful imaging of cusps and occluders with CT in normally functioning aortic and mitral replacement valves and the detection of a stuck mechanical leaflet.<sup>104-106</sup> CT of moving structures (cine CT), however, requires reconstruction of multiple phases of the cardiac cycle and at this time has limited temporal resolution.

CT can also image pannus<sup>107,108</sup> which may be difficult on TTE or TEE, particularly in the aortic position. Case reports suggest that vegetations can also be imaged.<sup>109</sup> Calcification on CT correlates approximately with the grade of stenosis on echocardiography in native valves<sup>110</sup> and could aid in the detection of early primary failure of biologic replacement valves.<sup>111</sup>

To date, there are no systematic studies comparing CT with echocardiography. At this time, there are no definitive indications for CT in assessing prosthetic heart valve dysfunction. However, early clinical experience shows that CT could be used as an alternative to fluoroscopy for mechanical valves and could be considered for imaging the cusps of biologic valves if the results of TEE are inconclusive.

**3. Cardiac Catheterization.** Measurements of flow and pressure gradients are used for the calculation of EOA using the Gorlin formula. Normal values of valve gradients and effective areas have been reported for several heart valves.<sup>112</sup> Contrast injection allows the assessment of prosthetic valve regurgitation. Ideally, a dual-catheter approach is needed to measure pressure upstream and downstream

from the valve. In clinical practice, however, this is not commonly performed. Crossing a prosthetic valve with a catheter should not be attempted in mechanical valves because of limitations and possible complications.<sup>113-115</sup> In prosthetic mitral valves, the use of pulmonary capillary wedge pressure for measurement of transmitral gradient frequently results in an overestimation of gradient and hence underestimation of valve area compared with direct measurement of LA pressure.<sup>17,116-118</sup> Thus, in the rare cases in which invasive mitral prosthetic gradients need to be assessed, a direct measurement of LA pressure with a transeptal technique is currently recommended. Tissue valves can be crossed with a catheter easily, but a degenerative, calcified bioprosthesis is friable, and leaflet rupture with acute severe regurgitation is possible. A dual-catheter technique for the measurement of gradients is still needed in rare cases of prosthetic aortic valves in which gradients cannot be adequately obtained by transthoracic Doppler echocardiography or TEE. Contrast angiography is occasionally used, along with TEE, in delineating associated complications of prosthetic valves, such as fistulas and pseudoaneurysms.

## G. Postoperative Evaluation and Follow-Up Studies

Ideally, a baseline postoperative transthoracic echocardiographic study should be performed at the first visit, 2 to 4 weeks after hospital discharge, when the chest wound has healed, ventricular function has improved, and anemia with its attendant hyperdynamic state has abated.<sup>1</sup> However if the patient is being transferred and may not return, it may be best to perform the study before hospital discharge.

Routine follow-up clinical visits should be conducted annually after valve replacement, with earlier reevaluations and echocardiography if there is a change in clinical status. Routine echocardiography after a first postoperative study is not indicated for normally functioning prostheses in the absence of associated pathology, other indications for echocardiography (eg, follow-up of LV dysfunction), or clinical symptoms suggestive of valvular dysfunction or other cardiac pathology.<sup>1</sup> Patients with bioprosthetic valves may be considered for annual echocardiography after the first 5 years in the absence of a change in clinical status. In patients with mechanical heart valves, routine annual echocardiography is not indicated in the absence of a change in physical examination or clinical status.<sup>1</sup>

## III. EVALUATION OF PROSTHETIC AORTIC VALVES

### A. Prosthetic Aortic Valve Function and Stenosis

**1. Imaging Considerations.** Echocardiographic imaging should identify the sewing ring, the valve or occluder mechanism, and the surrounding area. The ball or disc is often indistinctly imaged because of echo reverberations, whereas the leaflets of normal tissue valves should be thin with an unrestricted motion. Stentless or homograft valves may be indistinguishable from native valves. Imaging from the parasternal views should also be aimed at delineating well the LVO tract for measurement of LVO diameter to determine stroke volume and EOA. One can use modified views (lower parasternal location) to keep the artifact from the valve away from the LVO.

### 2. Doppler Parameters of Prosthetic Aortic Valve Function.

A complete examination includes an estimation of pressure gradients, DVI, EOA, an assessment of regurgitation if present, and LV size and function (Table 4).

**a. Velocity and Gradients.** Doppler velocity recordings across normal prosthetic valves usually resemble those of mild native aortic

stenosis, with a maximal velocity usually >2 m/s, along with a triangular shape of the velocity contour, with occurrence of the maximal velocity in early systole. With increasing stenosis of the valve, a higher velocity and gradient are observed, with longer duration of ejection and more delayed peaking of the velocity during systole (Figure 7). High gradients may be seen with normally functioning valves with a small size, increased stroke volume, PPM, or valve obstruction. Conversely, a mildly elevated gradient in the setting of severe LV dysfunction may indicate significant stenosis. Thus, the ability to distinguish malfunctioning from normal prosthetic valves in high flow states on the basis of gradients alone may be difficult. If the velocity in the LVO is >2 m/s, a suspicion of a dynamic or fixed obstruction exists upstream to the valve. In this situation, the estimated gradient through the prosthesis should reflect that it is a combined gradient. To minimize angle error, CW Doppler evaluation of aortic prostheses must be performed, similar to native aortic stenosis, from multiple transducer positions, including apical, right parasternal (with the patient in the right lateral decubitus position), right supraclavicular, and suprasternal notch (with the patient in a supine or semirecumbent position for these last two). Measurements of prosthesis velocity and gradients are made from the transducer position yielding the highest velocities. Occasionally, such as in patients with chronic lung disease, subcostal transducer positions yield the highest velocities.

For the adequate assessment of prosthetic valve function, other qualitative and quantitative indices that are less dependent on flow should be evaluated (Table 4). The contour of the velocity through the prosthesis is a qualitative but valuable index of prosthetic valve function that is used in conjunction with the other quantitative indices. In a normal valve, even during high flow, there is a triangular shape to the velocity, with early peaking of the velocity and a short acceleration time (AT; the time from the onset of flow to maximal velocity), similar to mild native aortic stenosis. With prosthetic valve obstruction, a more rounded velocity contour is seen, with the velocity peaking almost in mid-ejection, prolonged AT, ejection time (ET) as well as the AT/ET ratio (Figure 7).<sup>119,120</sup> These parameters are valuable in the overall assessment of valve function, particularly in high gradients. Recent data have shown that a cutoff of AT of 100 ms differentiates well between normal and stenotic prosthetic valves.<sup>119,121</sup> An AT/ET > 0.4 is also consistent with prosthetic valve obstruction.<sup>119,121</sup> These indices are independent of Doppler angulation with the jet direction. Other quantitative indices of valve function that are less dependent on flow are EOA and DVI.

b. EOA. Aortic EOA<sup>24,122,123</sup> is most often derived with stroke volume at the LVO as

$$EOA_{PrAV} = (CSA_{LVO} \times VTI_{LVO}) / VTI_{PrAV}$$

where  $CSA_{LVO}$  is the cross-sectional area of the outflow tract, derived from a diameter measurement just underneath the prosthesis from the parasternal long-axis view assuming a circular geometry, and  $VTI_{LVO}$  is the VTI proximal to the leaflets or occluder as recorded from an apical 5-chamber or long-axis view using PW Doppler (Figure 8). Care should be exercised in locating the sample volume adjacent to the prosthesis while avoiding the region of subvalvular acceleration (this usually requires a position 0.5 to 1 cm below the sewing ring (toward the apex). The Doppler waveform should be smooth, with minimal spectral broadening and a well-defined peak.  $VTI_{PrAV}$  is the VTI across the prosthesis using CW Doppler and is obtained from the same signals that are used for measurement of prosthesis peak velocity and mean gradient.

**Table 4** Doppler echocardiographic evaluation of prosthetic aortic valves

	Parameter
Doppler echocardiography of the valve	Peak velocity/gradient Mean gradient Contour of the jet velocity; AT DVI EOA
Pertinent cardiac chambers	Presence, location, and severity of regurgitation LV size, function, and hypertrophy

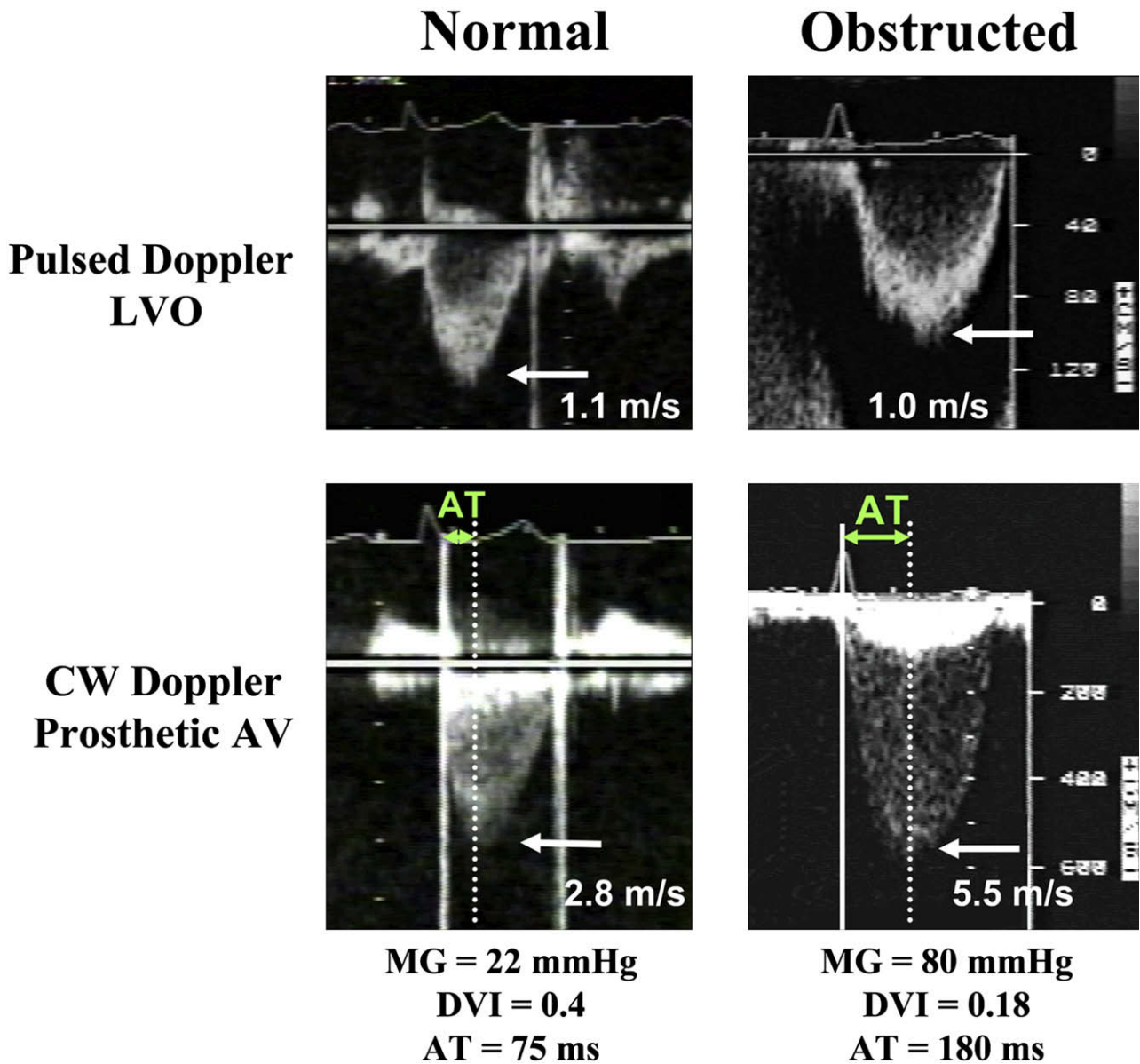
EOA, as expected, is dependent on the size of the inserted valve (Appendix A). EOA should therefore be referenced to the valve size of a particular valve type. For valves of any size, significant stenosis is suspected when valve area is <0.8 cm<sup>2</sup>. However, for the smallest size valve, this may still be normal, particularly for bileaflet valves because of pressure recovery (Appendix A). These are situations in which the size of the valve is crucial to know, and a comparison with a baseline postoperative study is helpful. The largest source of variability is measurement of the LVO tract. When this diameter is difficult to obtain, another site for flow measurement may be used. If TEE is performed, it offers an excellent opportunity for an LVO measurement.<sup>124</sup>

c. DVI. DVI is a dimensionless ratio of the proximal velocity in the LVO tract to that of flow velocity through the prosthesis:

$$DVI = V_{LVO} / V_{PrAV}$$

DVI is calculated as the ratio of respective VTIs and can be approximated as the ratio of the respective peak velocities (Figure 9).<sup>22</sup> DVI incorporates the effect of flow on velocity through the valve and is much less dependent on valve size.<sup>22</sup> DVI can therefore be helpful to screen for valve dysfunction, particularly when the cross-sectional area of the LVO tract cannot be obtained or valve size is not known. Part of the reason why DVI is less dependent on valve size is inherent in the relation of aortic valve size to the LVO cross-sectional area: the larger the LVO area, the larger the size of the valve that can be fitted at surgery.<sup>22</sup> DVI is always less than unity, because velocity will always accelerate through the prosthesis. A DVI < 0.25 is highly suggestive of significant valve obstruction. In a group of patients with severe stenosis of St Jude Medical aortic valves requiring reoperation, the mean DVI was 0.19 ± 0.05 (range, 0.12-0.27) and significantly lower compared with matched controls with normal prosthetic valve function (mean DVI, 0.39; range, 0.28-0.55).<sup>22,125</sup> Similar to EOA, DVI is not affected by high flow conditions through the valve, including AR, whereas blood velocity and gradient across the valve are.<sup>125</sup>

**3. Diagnosis of Prosthetic Aortic Valve Stenosis.** The appearance of a new murmur with new congestive heart failure symptoms in a patient with prosthetic aortic valve should prompt an urgent transthoracic study and, if indicated, TEE. However, the initial suspicion of prosthetic valve stenosis may be the incidental finding of abnormally high flow velocities detected during a routine examination. One must bear in mind that high velocity alone is not proof of intrinsic prosthetic obstruction and may be secondary to high flow or PPM. To the opposite, high gradients may not be manifest in patients with prosthesis dysfunction and low cardiac output state. Finally, Doppler recorded gradients may be spuriously elevated in bileaflet mechanical prostheses because of pressure recovery at the valvular level.



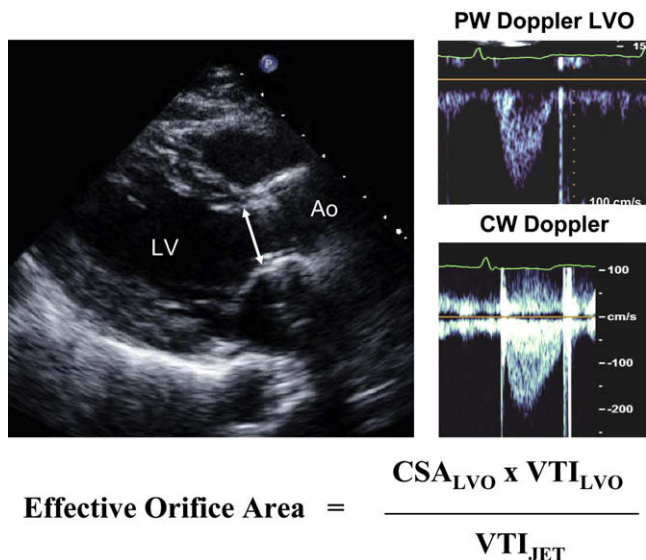
**Figure 7** Doppler recordings of a normal and obstructed prosthetic valve in the aortic position. With obstruction, the velocity of the jet is increased along with changes in the contour of the jet velocity to that of a parabolic, late peaking profile. The ET as well as the AT is increased. AT (in milliseconds) is measured as the duration from the onset of aortic ejection (*solid line*) to the maximal jet velocity (*dotted line*). Mean gradient (MG) is increased and the DVI is decreased with prosthetic obstruction.

There is significant variability in quantitative parameters of valve function because of different valve types and sizes. Individual valve parameters of velocity, gradients, and EOAs for various valve types and sizes in the aortic position are listed in [Appendix A](#).<sup>126</sup> While recognizing these differences, the writing group has provided general guidelines regarding parameters that should be measured and evaluated to assess aortic valve function. [Table 5](#) offers a general guide to collective normal values, intermediate values for which stenosis may be possible, and values that usually suggest obstruction in prosthetic aortic valves under normal or nearly normal cardiac output conditions. These in general apply to most prosthetic valves and exclude homografts, stentless valves, and percutaneous prostheses, because the latter have flow dynamics that are close to native valves.

In the presence of any abnormality of these parameters, a systematic assessment of the findings should be performed. The algorithm in

[Figure 10](#) proposes an approach to the evaluation of valves with an elevated peak velocity  $>3.0$  m/s. A DVI is calculated and its value integrated with information from the contour of the jet velocity. If the DVI is  $>0.25$  and the jet shows early peaking of the velocity (AT  $< 100$  ms),<sup>119,121</sup> most likely, the valve is normal, particularly if the other quantitative parameters fall in the normal or intermediate range ([Table 5](#)). In this case, the high velocity is most likely because of high flow, PPM, or pressure recovery from a bileaflet or caged-ball valve. Obstruction of the valve starts to be suspected when the DVI is  $<0.30$  and is highly suggested if the DVI is  $<0.25$  and the jet has a rounded contour, with late peaking of the velocity (AT  $> 100$  ms). The more abnormal the quantitative parameters, the more certainty there is regarding prosthetic obstruction.

In cases of discordance between information from the DVI and contour of the jet, considerations should be given to either valvular



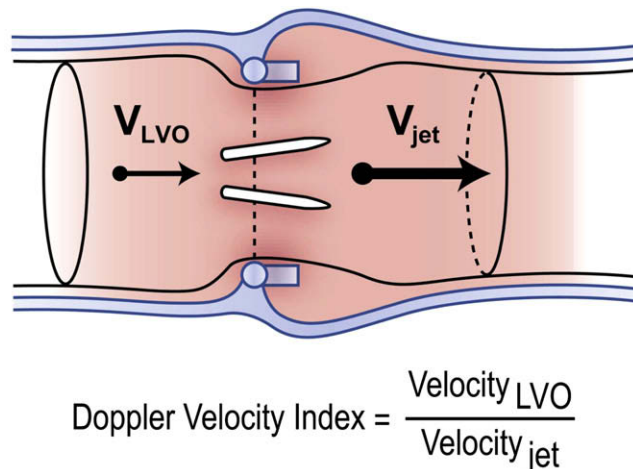
**Figure 8** Derivation of EOA of a prosthetic valve in the aortic position by Doppler echocardiography. The diameter of the LVO tract, just below the insertion of the prosthetic aortic valve, is shown. Note that the tip of the anterior arrow is at the junction of sewing ring and ventricular septum, and the tip of the posterior arrow is at the junction (pivot point) between the sewing ring and the base of the anterior mitral leaflet. Once the diameter has been measured, pulsed Doppler in the LVO tract from the apical window combined with CW Doppler recording is used to complete the data acquisition for EOA calculation. CSA, Cross-sectional area derived from diameter measurement assuming a circular geometry.

dysfunction or technical issues. In a normal DVI of  $>0.30$  but a rounded contour and an AT  $> 100$  ms, prosthetic stenosis should be considered, the reason for the elevated LVO velocity being either improper position of PW Doppler sample volume (too close to the valve, causing high velocity recording in the LVO) or subvalvular narrowing. Alternatively, the gradient through the prosthesis may be underestimated by improper CW Doppler recording because of problems of angulation of ultrasound with the stenotic jet. In the converse situation of a low DVI ( $<0.25$ ) and a normal contour of the jet and an AT  $< 100$  ms, an improper LVO velocity recording is most likely the situation (sample volume position too far apical from the prosthesis).

If the diagnosis of valve obstruction is in question, confirmation of the abnormality in valve motion is undertaken with TEE and/or fluoroscopy or CT. Although TEE can help evaluate complications of a valve, such as dehiscence, endocarditis, or thrombus formation, leaflet mobility in the aortic position is not optimally assessed with TEE in mechanical valves. In the latter situation, fluoroscopy and CT are very helpful to visualize mobility of the occluder.

## B. Prosthetic Aortic Valve Regurgitation

**1. Imaging Considerations.** TTE is useful to identify the presence of both paravalvular and intravalvular prosthetic AR. Acoustic shadowing, so problematic with mitral prostheses, is less of an issue for prosthetic AR (Figure 4). The optimal views for the detection of regurgitant jets include the parasternal long-axis and short-axis views, the apical long-axis view, and the 5-chamber view. Off-axis views may be helpful in localizing regurgitant jets and determining their origin.



**Figure 9** Schematic representation of the concept of the DVI. Velocity across the prosthesis is accelerated through the jet from the LVO tract. DVI is the ratio velocity in the LVO ( $V_{\text{LVO}}$ ) to that of the jet ( $V_{\text{jet}}$ ).

In the parasternal short-axis view, color flow Doppler interrogation of the sewing ring may be able to localize and define the extent of a perivalvular leak. However, in this view, acoustic shadowing may obscure jets in the region of the noncoronary sinus.

**2. Doppler Evaluation of Severity of Prosthetic AR.** Few studies have attempted to quantitate the severity of prosthetic AR.<sup>127</sup> Rallidis et al<sup>127</sup> classified mild AR as a narrow turbulent jet, with a ratio of jet diameter/LVO diameter of  $<25\%$ . Broader jets were classified as moderate or severe, depending on other criteria, such as the pressure half-time or the presence of holodiastolic flow reversal in the descending aorta.<sup>127</sup> The integrative approach recommended for native aortic valve regurgitation should be applied to prosthetic AR, with several caveats and modifications<sup>16</sup> (Table 6), as noted below.

**a. Color Doppler.** With color Doppler, an evaluation of the components of the color AR jet (flow convergence, vena contracta, and extent in the LVO and left ventricle), its origin, and its direction is necessary for an accurate evaluation. Normal “physiologic” jets will usually be low in momentum, as shown by homogeneous color jets that are small in extent. The ratios of jet diameter/LVO diameter from parasternal long-axis imaging and jet area/LVO area from parasternal short-axis imaging of the LVO just below the prosthesis, as parameters of AR severity, are best applied in central jets. In certain instances, acoustic shadowing directly below the valve may obscure accurate measurement of jet width in the LVO. As AR jets may often be eccentric, measurement of the jet width perpendicular to the LVO tract will cut the jet obliquely and risk overestimation (Figure 11). Last, and similar to native AR, entrainment of the jet in the LVO tract may lead to rapid broadening of the jet just after the vena contracta and thus to overestimation of regurgitant severity. Conversely, jets of significant AR may be so eccentric as to impinge on the wall of the LVO or anterior mitral valve and be less impressive on color Doppler. In these instances, integration of the evaluation by other Doppler parameters is necessary.

In contrast to native valves, the width of the vena contracta, as a parameter of AR severity, may be difficult to accurately measure in the long axis in the presence of a prosthesis. Careful imaging of the neck of the jet in a short-axis view, at the level of the prosthesis sewing ring, allows determination of the circumferential extent of the

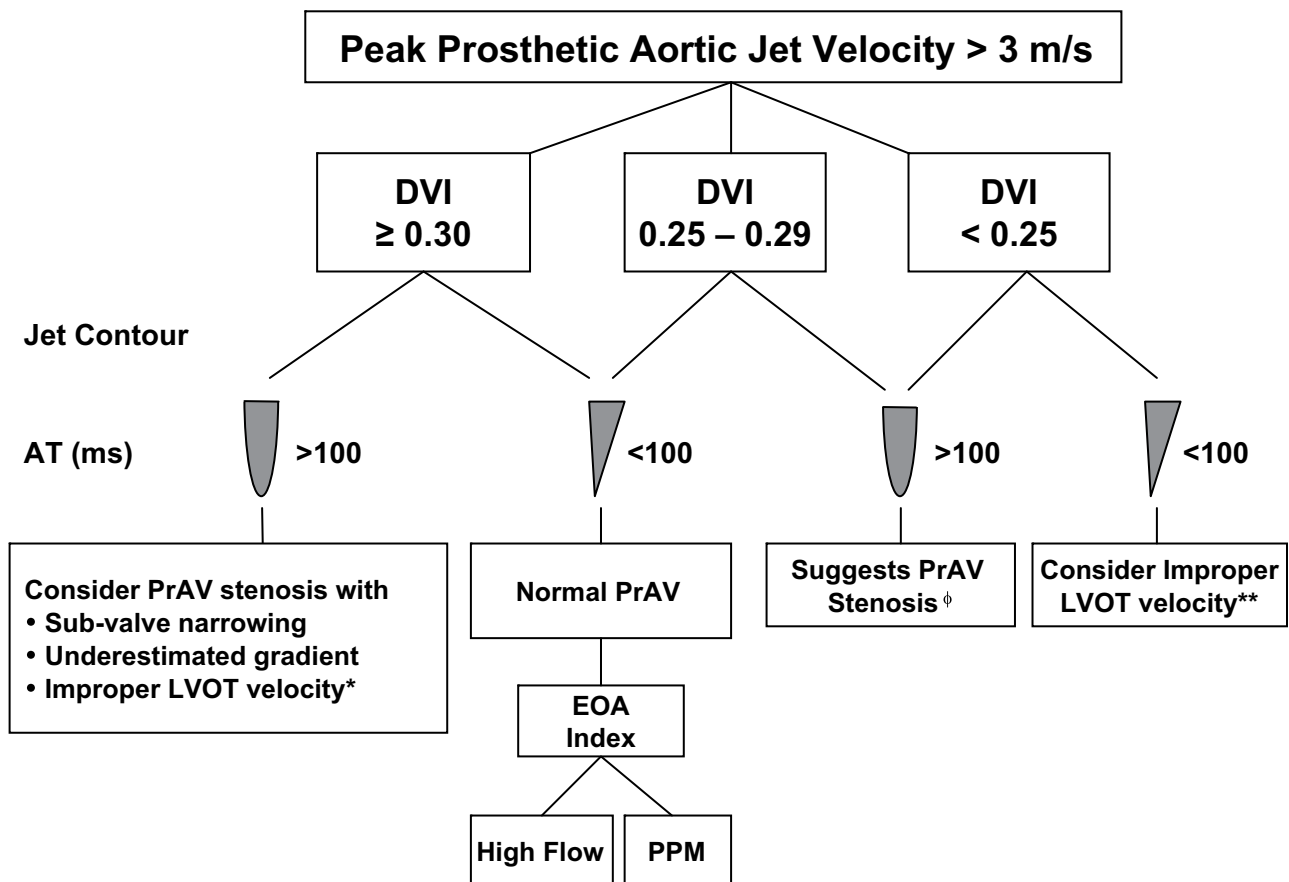
**Table 5** Doppler parameters of prosthetic aortic valve function in mechanical and stented biologic valves\*

Parameter	Normal	Possible stenosis	Suggests significant stenosis
Peak velocity (m/s) <sup>†</sup>	<3	3-4	>4
Mean gradient (mm Hg) <sup>†</sup>	<20	20-35	>35
DVI	≥0.30	0.29-0.25	<0.25
EOA (cm <sup>2</sup> )	>1.2	1.2-0.8	<0.8
Contour of the jet velocity through the PrAV	Triangular, early peaking	Triangular to intermediate	Rounded, symmetrical contour
AT (ms)	<80	80-100	>100

PrAV, Prosthetic aortic valve.

\*In conditions of normal or near normal stroke volume (50-70 mL) through the aortic valve.

†These parameters are more affected by flow, including concomitant AR.



**Figure 10** Algorithm for evaluation of elevated peak prosthetic aortic jet velocity incorporating DVI, jet contour, and AT. \*PW Doppler sample too close to the valve (particularly when jet velocity by CW Doppler is  $\geq 4$  m/s). \*\*PW Doppler sample too far (apical) from the valve (particularly when jet velocity is 3-3.9 m/s).  $\phi$  Stenosis further substantiated by EOA derivation compared with reference values if valve type and size are known. Fluoroscopy and TEE are helpful for further assessment, particularly in bileaflet valves. AVR, Aortic valve replacement.

regurgitation in the case of paravalvular regurgitation as a semiquantitative measure of severity. As an approximate guide, <10% of the sewing ring suggests mild, 10% to 20% suggests moderate, and >20% suggests severe. Rocking of the prosthesis is usually associated with >40% dehiscence.<sup>12</sup>

b. Spectral Doppler. Semiquantitative and quantitative methods that are not influenced by the presence of the prosthesis should also be used in assessing AR severity. The pressure half-time is useful when the value is <200 ms, suggesting severe regurgitation, or >500 ms, consistent with mild regurgitation. However, intermediate ranges

of pressure half-time (200-500 ms) may reflect other hemodynamic variables such as LV compliance and are less specific.<sup>16</sup> The presence of holodiastolic flow reversal in the descending thoracic aorta is indicative of at least moderate AR; severe AR is suspected when the VTI of the reverse flow approximates that of the forward flow (Figure 11). Holodiastolic flow reversal in the abdominal aorta is usually indicative of severe AR. Regurgitant volume can be calculated as the difference between stroke volume at the LVO (or 2D-derived total LV stroke volume) and the transmitral or pulmonary flow. Cut points for severity are similar to those for AR of native valves.<sup>16</sup> Care should be exercised in measuring the flow integral in the LVO tract. When the sample volume



**Table 6** Parameters for evaluation of the severity of prosthetic aortic valve regurgitation

Parameter	Mild	Moderate	Severe
Valve structure and motion			
Mechanical or bioprosthetic	Usually normal	Abnormal <sup>†</sup>	Abnormal <sup>†</sup>
Structural parameters			
LV size	Normal <sup>‡</sup>	Normal or mildly dilated <sup>‡</sup>	Dilated <sup>‡</sup>
Doppler parameters (qualitative or semiquantitative)			
Jet width in central jets (% LVO diameter): color*	Narrow ( $\leq 25\%$ )	Intermediate (26%-64%)	Large ( $\geq 65\%$ )
Jet density: CW Doppler	Incomplete or faint	Dense	Dense
Jet deceleration rate (PHT, ms): CW Doppler <sup>§</sup>	Slow ( $>500$ )	Variable (200-500)	Steep ( $<200$ )
LVO flow vs pulmonary flow: PW Doppler	Slightly increased	Intermediate	Greatly increased
Diastolic flow reversal in the descending aorta: PW Doppler	Absent or brief early diastolic	Intermediate	Prominent, holodiastolic
Doppler parameters (quantitative)			
Regurgitant volume (mL/beat)	$<30$	30-59	$>60$
Regurgitant fraction (%)	$<30$	30-50	$>50$

PHT, Pressure half-time.

\*Parameter applicable to central jets and is less accurate in eccentric jets; Nyquist limit of 50 to 60 cm/s.

<sup>†</sup>Abnormal mechanical valves, for example, immobile occluder (valvular regurgitation), dehiscence or rocking (paravalvular regurgitation); abnormal biologic valves, for example, leaflet thickening or prolapse (valvular), dehiscence or rocking (paravalvular regurgitation).

<sup>‡</sup>Applies to chronic, late postoperative AR in the absence of other etiologies.

<sup>§</sup>Influenced by LV compliance.

is placed too close to the prosthetic valve, proximal acceleration may lead to overestimation of velocity and thus of regurgitant volume.

Although left-sided volume overload is expected in the presence of hemodynamically significant AR, LV volumes may reflect the preoperative state, especially in cases of early postoperative prosthetic regurgitation. However, if LV volumes fail to decrease after valve replacement for AR, a hemodynamically significant leak should be suspected among other factors.

**3. Role of TEE in Prosthetic AR.** The role of TEE in prosthetic AR is to better identify its site in technically difficult transthoracic echocardiographic studies (valvular vs paravalvular) and delineate the mechanism of regurgitation and associated complications such as endocarditis, abscess formation, masses, or thrombus that interfere with disc function.<sup>128</sup> Posterior paravalvular leaks that were not visible on surface imaging may be evident, and it may be possible to map the full extent of dehiscence leading to regurgitation.<sup>8,71</sup> The long-axis view is useful for measuring jet width and the ratio of jet width to LVO tract width for the evaluation of severity. TEE may be limited in evaluating prosthetic AR in the midesophageal level because of acoustic shadowing anteriorly. Importantly, the presence of a concomitant mitral prosthesis will cause significant shadowing and obscure the LVO tract.<sup>129,130</sup> In such cases it is critical to evaluate the prosthesis from transgastric transducer positions.

#### 4. An Integrative Approach in Evaluating Prosthetic AR.

Assessment of severity of AR is in general more difficult than in native valves because of the high prevalence of paravalvular regurgitation and eccentric jets. The process of grading AR should be comprehensive and integrative, using a combination of the qualitative and semi-quantitative parameters shown in Table 6. If the AR is definitely determined as mild or less using these parameters, no further measurement is required. If there are parameters suggestive of more than mild AR and the quality of the data lends itself to quantitation, it is desirable to measure quantitatively the degree of AR, including the regurgitant volume and fraction. When the evidence from the different parameters is concordant, it is easy to grade AR severity. When parameters are contradictory, one must look carefully for technical and physiologic reasons to explain these discrepancies and rely on

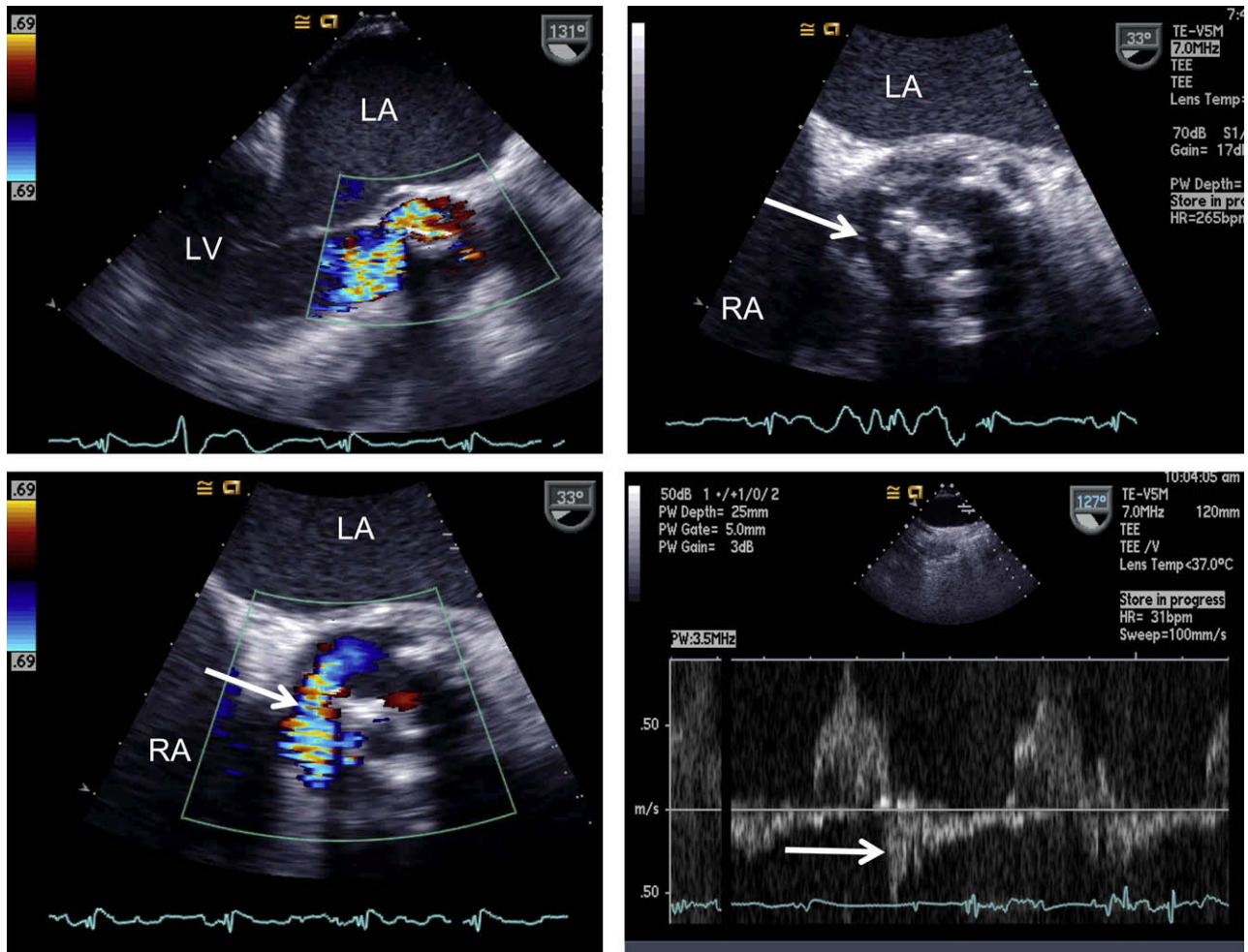
the components that have the best quality and are the most accurate, considering the presence of a prosthetic valve and the underlying clinical condition. TTE may be adequate for most of the qualitative and quantitative information needed to evaluate AR severity. TEE complements the transthoracic approach in technically difficult studies, in mapping the extent of annular involvement, and in evaluating the etiology of AR and associated complications.<sup>131</sup>

## IV. EVALUATION OF PROSTHETIC MITRAL VALVES

### A. Prosthetic Mitral Valve Function and Stenosis

**1. Imaging Considerations.** With the availability of several windows on TTE, recording of jet velocity across the prosthetic mitral valve is readily feasible to evaluate prosthetic valve function. However, a major consideration in the evaluation of prosthetic mitral valve function by echocardiography is the effect of acoustic shadowing by the prosthesis on assessment of MR<sup>132</sup> (Figure 4). This problem is worse with mechanical valves than with bioprosthetic valves. On TTE, LV function is readily evaluated, but the left atrium is often obscured for imaging and Doppler interrogation. In contrast, TEE provides excellent visualization of the left atrium and MR, but acoustic shadowing limits visualization of the left ventricle (Figure 12). Thus, a comprehensive assessment of prosthetic mitral valve function often requires both transthoracic and transesophageal imaging when valve dysfunction is suspected clinically or on TTE.

**a. Parasternal Views.** In the parasternal long-axis view, the mitral valve prosthesis may obscure portions of the left atrium and its posterior wall.<sup>132</sup> This may prevent detection of small degrees of MR or make it difficult to determine the precise origin or vena contracta of an MR jet (Figure 4). The parasternal long-axis view allows visualization the LVO tract, which can be impinged by higher profile prostheses. This can lead to LVO turbulence and at times significant LVO tract gradient. The short-axis view at the level of the prosthesis allows visualization of the leaflet excursion and sewing ring of a bioprosthetic mitral valve. It may allow determination of the circumferential extent of



**Figure 11** Transesophageal images of a patient with perivalvular significant AR demonstrating (arrows) the extent of dehiscence and regurgitation in cross-section and diastolic flow reversal in the descending aorta. Flow convergence in the aortic root, vena contracta, and an eccentric jet directed anteriorly in the LVO toward the septum (left upper panel) are seen. Because of jet eccentricity, measurement of jet width to LVO diameter is not advised in this case. See Videos 11 and 12. [View video clips online.](#)

a paravalvular leak by color flow mapping. For mechanical valves, the short-axis view is limited by acoustic shadowing of the posterior aspect of the valve sewing ring.

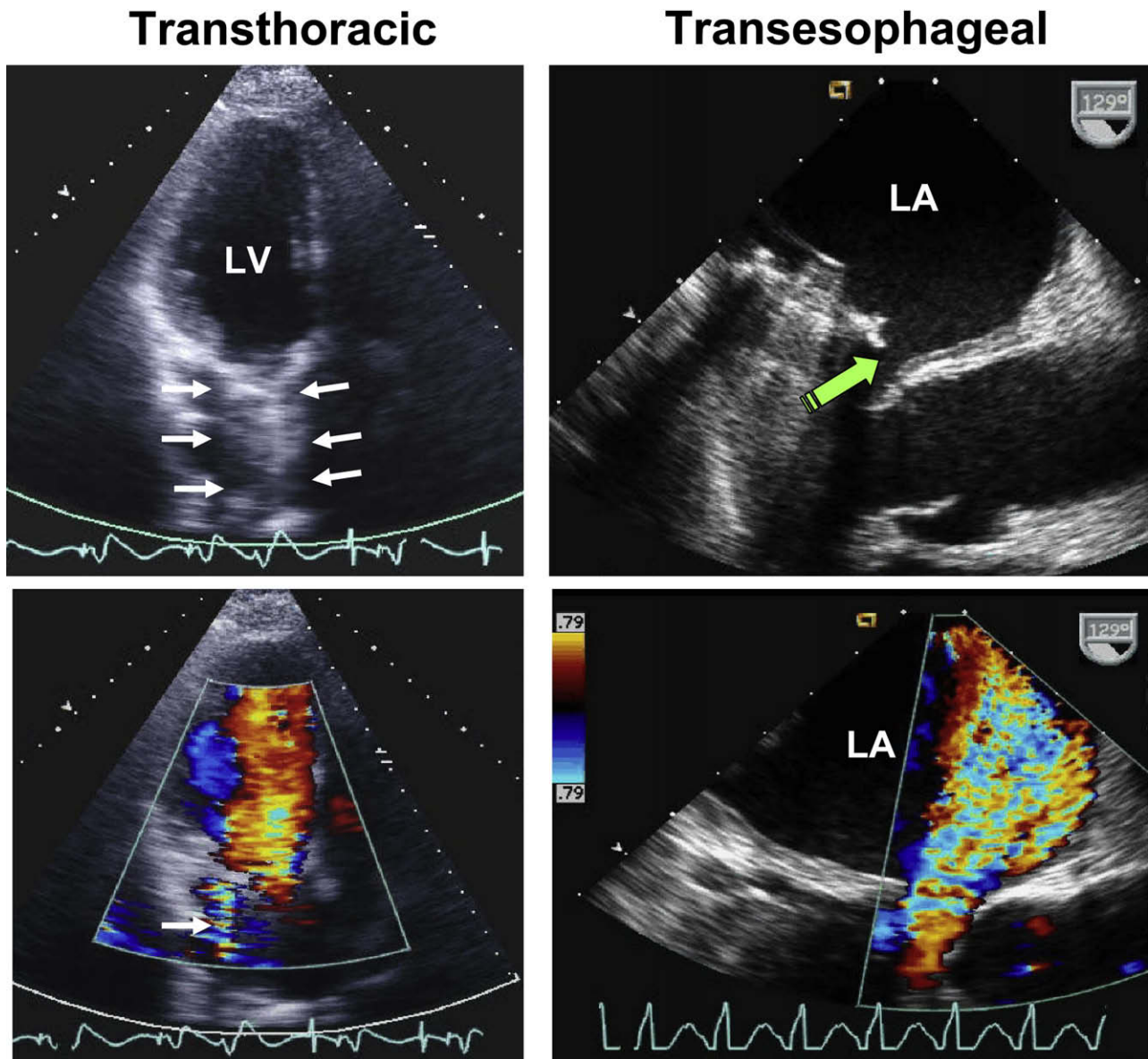
**b. Apical Views.** The apical views allow visualization of leaflet excursion for both bioprosthetic and mechanical valve prostheses. Muratori et al<sup>133</sup> showed a high concordance between leaflet excursion measurements by echocardiography (85% on TTE and 100% on TEE) and cinefluoroscopy for mitral valve prostheses. Apical views may allow the detection of thrombus or pannus that might limit leaflet excursion. Vegetations can be seen but often are masked by acoustic shadowing, which also limits the assessment of MR from apical windows.<sup>132</sup> Despite this problem, paravalvular leaks may be seen because their origin is outside the sewing ring, and significant regurgitation is often suspected from the presence of proximal flow convergence on the LV side of the prosthesis.<sup>134</sup> The apical views almost always allow well-aligned parallel Doppler velocity recordings of forward flow through the prosthesis orifice. This yields important information about prosthetic valve function, such as peak velocity, peak and mean pressure gradient, and comparison of transmitral to LVO VTIs and derivation of their ratio (Figure 13). In certain normal valves or in obstructed valves, the inflow jet may be very eccentric

such that the least angulation with flow is obtained from a parasternal or lateral approach. Color flow Doppler is very helpful in evaluating the direction of flow into the left ventricle, thus further optimizing spectral Doppler recordings of jet velocity.

## 2. Doppler Parameters of Prosthetic Mitral Valve Function.

A complete examination should include peak early velocity, estimation of mean pressure gradient, heart rate, pressure half-time, and determination of whether regurgitation is present or suspected. A DVI and/or EOA may be determined, as needed, for further refinement. Other evaluation should include the determination of LV and RV size and function, LA size if possible, and an estimation of pulmonary artery systolic pressure (Table 7).

**a. Peak Early Mitral Velocity.** The peak E velocity is easy to measure and provides a simple screen for prosthetic valve dysfunction.<sup>135</sup> The peak velocity can be elevated in hyperdynamic states, tachycardia, small valve size, stenosis, or regurgitation. Tachycardia exerts a particularly important effect on velocity and gradient measurements in the mitral position because of the associated shortening of the diastolic filling period. In addition, inhomogeneous flow profiles across caged-ball and bileaflet prostheses can lead to Doppler velocity

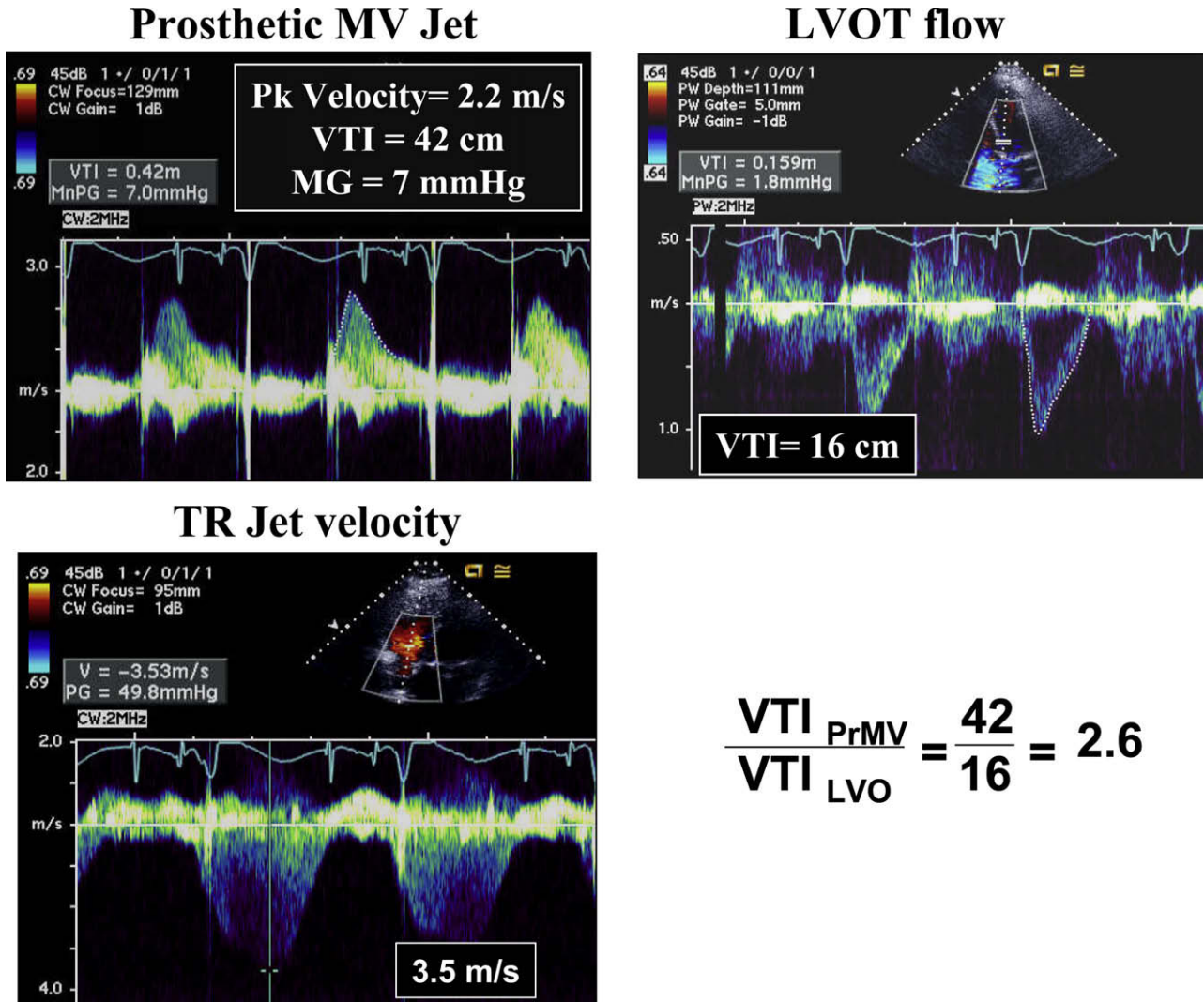


**Figure 12** Transthoracic versus transesophageal echocardiographic and Doppler images in a patient with severe paravalvular MR. Shadowing on TTE of the left atrium (*arrows*) masked significantly the regurgitant jet by color Doppler (*single white arrow*). The extent of valvular dehiscence is shown by the *green arrow* on TEE as well as the severity of regurgitation by color Doppler. See Videos 13 to 16. [View video clips online.](#)

measurements that are elevated out of proportion to the actual measured gradient.<sup>18,136,137</sup> For normally functioning bioprosthetic mitral valves, peak velocity can range from 1.0 to 2.7 m/s.<sup>138,139</sup> In normally functioning bileaflet mechanical valves, the peak velocity is usually <1.9 m/s but can be up to 2.4 m/s.<sup>135,139,140</sup> As a general rule, however, a peak velocity <1.9 m/s is likely to be normal in most patients with mechanical valves unless there is markedly depressed LV function. If the peak velocity is  $\geq 1.9$  m/s in a mechanical valve, one should consider a normally functioning valve with a high velocity versus prosthetic valve dysfunction (stenosis or regurgitation).<sup>135,139,140</sup> This cut-off may be slightly higher in some bioprosthetic valves. If leaflet excursion is seen to be normal, there is no vegetation or thrombus, and there is no MR, it is likely the former. Because MR also increases transmitral flow velocity, patients with elevated peak E velocity may require TEE to exclude significant MR.

**b. Mean Gradient.** Mean gradient is also useful in assessing prosthetic mitral valve function and is normally <5 to 6 mm Hg.<sup>55,141</sup> However, values up to 10 and 12 mm Hg have been reported in normally functioning Starr-Edwards and St Jude bileaflet prostheses, respectively,<sup>140,142</sup> highlighting the need to compare serial values in the same patient over time. High mean gradients may be due to hyperdynamic states, tachycardia or PPM, regurgitation, or stenosis. The mean gradient is significantly affected by heart rate, so the heart rate at which the mean gradient is measured should always be reported.

**c. Pressure Half-Time.** The rate of blood flow across the mitral valve is dominated by the mitral orifice area in the presence of moderate or severe stenosis. However, when the mitral stenosis is only mild or there is a normally functioning valve, the rate of flow also



**Figure 13** Transthoracic Doppler echocardiographic clues for significant mechanical MR. These recordings are for the same patient as in Figure 12. Peak early velocity, VTI of the jet, and mean gradient are higher than normal. In the presence of normal LV function, the VTI in the LVO tract is decreased with a resultant increase in the DVI. The TR jet velocity indicates pulmonary hypertension.

depends on atrial and ventricular compliance, ventricular relaxation, and the pressure difference at the start of diastole. Thus, a large rise in pressure half-time on serial studies or a markedly prolonged single measurement (>200 ms) may be a clue to the presence of prosthetic valve obstruction, because the pressure half-time seldom exceeds 130 ms across a normally functioning mitral valve prosthesis<sup>135,140</sup> (Figure 14). However, minor changes in pressure half-time occur as a result of nonprosthetic factors, including loading conditions, drugs, or aortic insufficiency. Pressure half-time should not be obtained in tachycardic rhythms or first-degree atrioventricular block when E and A velocities are merged or the diastolic filling period is short.

d. EOA. Calculation of EOA from pressure half-time, as traditionally applied in native mitral stenosis, is not valid in prosthetic valves, because of its dependence on LV and LA compliance and initial LA pressure.<sup>34,55</sup> Therefore, EOA calculation by the continuity equation is preferable to that measured by pressure half-time in mitral prostheses. In bileaflet valves, the smaller central orifice has a higher velocity than the larger outside orifices, which may lead to underestimation of EOA by the continuity equation.<sup>55</sup> Thus, the accuracy of EOA by the con-

tinuity equation may be better for bioprosthetic valves and single tilting disc mechanical valves. EOA is derived as stroke volume through the prosthesis divided by the VTI of the mitral jet velocity:

$$\text{EOA}_{\text{PrMV}} = \text{stroke volume} / \text{VTI}_{\text{PrMV}}$$

Stroke volume through the mitral valve is equated with that through the LVO when there is no significant MR or AR. Normative information on EOA and EOA indexed to body surface area is available for several types of prostheses in the mitral position.<sup>55,142-144</sup> The use of effective areas is usually reserved for cases of discrepancy between information obtained from gradients and pressure half-time. Although derivation of EOA for prosthetic mitral valves is less often used, it is strongly advisable to note the VTI of the prosthetic valve, because it is much less dependent on heart rate compared with mean gradient. VTI of the prosthetic mitral jet is particularly useful in tachycardic and bradycardic states in which gradients may be misleading (high and low, respectively), and a derivation of EOA is readily obtained with the use of  $\text{VTI}_{\text{PrMV}}$  and an estimate of stroke volume (by echocardiography or Doppler).

**Table 7** Echocardiographic and Doppler parameters in evaluation of prosthetic mitral valve function (stenosis or regurgitation)

Doppler echocardiography of the valve	Peak early velocity Mean gradient Heart rate at the time of Doppler Pressure half-time DVI*: $VTI_{PrMV}/VTI_{LVO}$ EOA* Presence, location, and severity of regurgitation†
Other pertinent echocardiographic and Doppler parameters	LV size and function LA size‡ RV size and function Estimation of pulmonary artery pressure

*PrMV*, Prosthetic mitral valve.

\*These indices are used when further information is needed about valve function. EOA is calculated using the continuity equation.

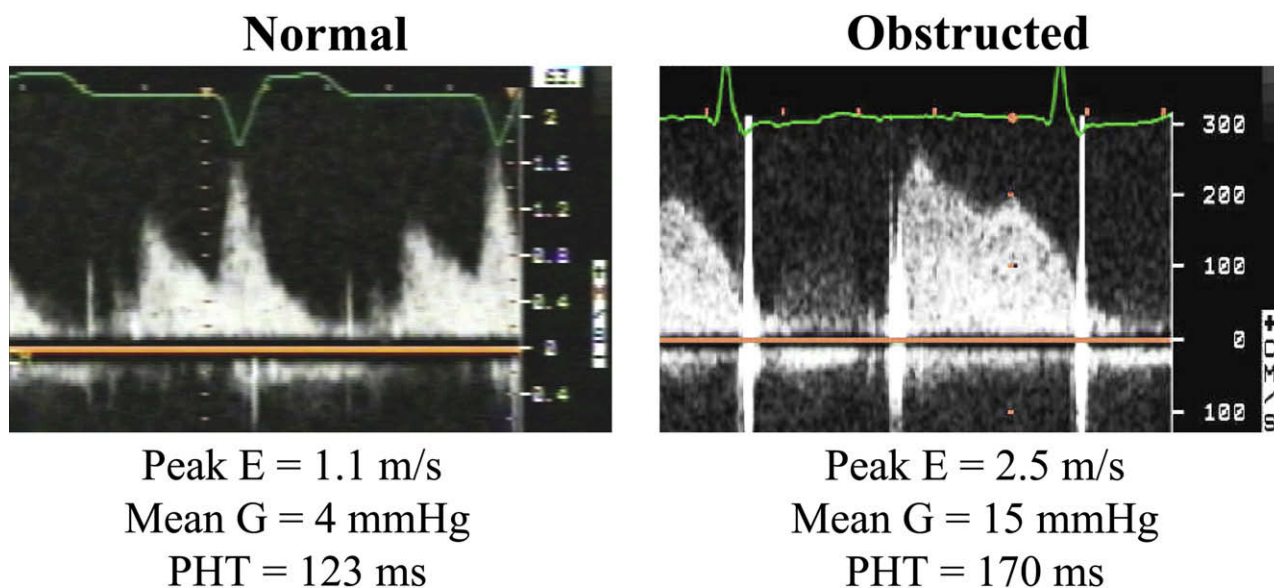
†Often needs transesophageal echocardiographic evaluation because of acoustic shadowing.

‡May be difficult in the presence of shadowing or reverberation from the valve.

Recently, values of this ratio have been reported for a large number of patients with Carpentier-Edwards Duraflex bioprostheses (Edwards Lifesciences) and appear to be normally higher than for normal mechanical valves.<sup>144</sup>

Because atrial fibrillation is frequent in patients with prosthetic mitral valves, close attention to matching cardiac cycles is crucial in the derivation of either EOA or the  $VTI_{PrMV}/VTI_{LVO}$  ratio, because both parameters are derived from different cardiac cycles. The preceding R-R interval to LVO velocity is matched to the R-R interval of mitral inflow velocity.

**3. Diagnosis of Prosthetic Mitral Valve Stenosis.** Significant valve obstruction may be obvious because of cusp thickening or reduced mobility. Failure of the color map to fill the orifice in all views is helpful if it is difficult to image the occluder. The initial impression will be corroborated by elevated peak E velocity and mean gradient, prolonged pressure half-time, and/or raised  $VTI_{PrMV}/VTI_{LVO}$  ratio. Table 8 lists the various Doppler parameters that are helpful in the evaluation of prosthetic mitral valve function, on the basis of available data from the literature and the consensus of the task force members. Cutoffs are probably different for bioprosthetic valves (Appendix B). When all parameters are normal, the probability of valve dysfunction is very low (0% stenosis, 2% regurgitation).<sup>135</sup> If the majority of



**Figure 14** Doppler velocity patterns observed in a normal and an obstructed prosthetic valve in the mitral position. The velocity and gradients are elevated as well as pressure half-time in the obstructed valve.

e. DVI. Fernandes et al<sup>135</sup> proposed the use of the ratio of the VTIs of the mitral prosthesis to the LVO tract ( $VTI_{PrMV}/VTI_{LVO}$ ) as an index of mechanical mitral prosthetic valve function. This DVI is the inverse of that proposed for prosthetic aortic valves (Figure 13). The concept is important in that elevated transmitral velocities can occur in the setting of prosthetic valve stenosis, regurgitation, or high output states. In high output states, the ratio is unchanged, because the increase in velocity occurs across both the LVO and the prosthetic valve. However, the  $VTI_{PrMV}/VTI_{LVO}$  ratio would be elevated either in stenosis (increased velocity across the valve) or regurgitation (increased velocity across the valve and decreased velocity in the LVO). In mechanical valves, a  $VTI_{PrMV}/VTI_{LVO} < 2.2$  is most often normal.<sup>135</sup> Higher values should prompt consideration of prosthetic valve dysfunction.

parameters are abnormal, the predictive value for abnormal valvular function is 100%. An increased pressure half-time (or decreased EOA) in the presence of other abnormal parameters of elevated velocity and gradients points to valve stenosis as opposed to regurgitation.<sup>135</sup> When quantitative Doppler measures are of uncertain significance or somewhat discordant, one must determine whether the abnormal values reflect true prosthetic valve dysfunction or are altered despite normal prosthetic valve function because of situations such as high output states, tachycardia, or PPM. Thus, knowledge of the size of the implanted valve and its baseline Doppler parameters or previous TEE for serial comparison cannot be overemphasized. It is also important to examine the anatomy of the leaflets for normal excursion, vegetations, pannus, or thrombus, as well as to look for

**Table 8** Doppler parameters of prosthetic mitral valve function

	Normal*	Possible stenosis <sup>‡</sup>	Suggests significant stenosis* <sup>‡</sup>
Peak velocity (m/s) <sup>† §</sup>	<1.9	1.9-2.5	≥2.5
Mean gradient (mm Hg) <sup>† §</sup>	≤5	6-10	>10
VTI <sub>PrMV</sub> /VTI <sub>LVO</sub> <sup>† §</sup>	<2.2	2.2-2.5	>2.5
EOA (cm <sup>2</sup> )	≥2.0	1-2	<1
PHT (ms)	<130	130-200	>200

PHT, Pressure half-time; PrMV, prosthetic mitral valve.

\*Best specificity for normality or abnormality is seen if the majority of the parameters listed are normal or abnormal, respectively.

†Slightly higher cutoff values than shown may be seen in some bioprosthetic valves.

‡Values of the parameters should prompt a closer evaluation of valve function and/or other considerations such as increased flow, increased heart rate, or PPM.

§These parameters are also abnormal in the presence of significant prosthetic MR.

rocking or dehiscence of the sewing ring or a echo-free space adjacent to the sewing ring consistent with pseudoaneurysm or abscess.<sup>145-147</sup> TEE should be considered because of its outstanding visualization of the structure and function of mitral valve prostheses of all types to make the diagnosis of obstruction when this is uncertain after TTE and in all cases to differentiate the possible causes of obstruction, particularly if thrombolysis is contemplated.<sup>86</sup>

## B. Prosthetic Mitral Valve Regurgitation

**1. Imaging Considerations.** Given that direct detection of prosthetic MR is often not possible with transthoracic Doppler techniques, particularly in mechanical valves, one must rely on indirect signs suggestive of significant MR on TTE (Table 9). These include a hyperdynamic LV with low systemic output, an elevated mitral E velocity, an elevated VTI<sub>PrMV</sub>/VTI<sub>LVO</sub> ratio, a dense CW regurgitant jet with early systolic maximal velocity, a large zone of systolic flow convergence toward the prosthesis seen in the LV, or a rise in pulmonary artery pressure compared with an earlier study<sup>148</sup> (Figure 13). Pressure half-time is often normal in prosthetic MR unless there is concomitant stenosis.<sup>135,148</sup> Of the findings listed, the most accurate are those that reflect an increase in flow through the prosthesis (peak early velocity ≥ 1.9 m/s in mechanical valves, mean gradient ≥ 6 mm Hg), particularly when the high flow is not proportional to the flow ejected systemically (VTI<sub>PrMV</sub>/VTI<sub>LVO</sub> > 2.2).<sup>135,148</sup> The presence of any of these findings in a patient with appropriate clinical symptoms represents a clear indication for TEE.

**2. Role of TEE.** TEE is highly sensitive and specific in detecting prosthetic MR and assessing its mechanism.<sup>149-151</sup> However, the assessment of severity is still achieved best by combining TEE with transthoracic examination. The sensitivity of TEE is high, such that the "built-in" trivial MR needs to be differentiated from pathologic MR. Paravalvular leaks on color Doppler have a typical appearance of a jet that passes from the left ventricle into the left atrium outside the surgical ring and often projects into the atrium in an eccentric direction (Figure 12). Because the regurgitation may be present anywhere around the circumference of the ring, it is essential that the valve be inspected in multiple planes. It is also crucial to show the origin of the jet as it passes through the area of dehiscence, its flow convergence and vena contracta. In patients with prosthetic valve endocarditis,

a perivalvular abscess may create a fistula between the left ventricle and left atrium that functions like a paravalvular leak. In addition to interrogation of the jet by CW Doppler, TEE allows a better recording of the pulmonary venous flow to corroborate the assessment of MR severity. Systolic flow reversal is specific for severe MR,<sup>16</sup> provided that the MR jet is not directed into the interrogated vein.

**3. Assessment of Severity of Prosthetic MR.** Assessment of severity of prosthetic MR can be difficult at times because of the lack of a single quantitative parameter that can be applied consistently in all patients. The only methodology that one could apply to compute a regurgitant volume consists of deriving a total LV stroke volume by 2D echocardiography and subtracting from it the stroke volume across the LVO (or RV outflow). However, this method relies on an accurate determination of LV volumes by 2D echocardiography, and to date, it has not been properly validated. Three-dimensional echocardiography may facilitate this approach.<sup>152</sup> Consequently, the best methodology at this time is to integrate several findings from both TTE and TEE that together suggest a given severity of regurgitation (Table 10).

A well preserved LV ejection fraction > 60% with normal size or enlarged left ventricle, along with a relative reduction in LVO or RV outflow stroke volume, should raise the possibility that the MR is significant. TEE is often needed to complete the assessment of prosthetic MR severity and complement the transthoracic echocardiographic findings. Distinction of mild from moderate or severe prosthetic MR is usually possible with the findings below. By contrast, it is more difficult to discriminate moderate from severe MR. As with native MR, regurgitant jet area reflects MR severity when the jets are central in origin, as seen with tissue valve degeneration, and works best at the extremes (ie, mild versus severe). A small thin jet (jet area < 4 cm<sup>2</sup>) in the left atrium usually reflects mild MR, while a large, wide jet (≥8 cm<sup>2</sup>) reflects a moderate or severe lesion.<sup>153</sup> Maximal width of the vena contracta is the index that best relates with angiographic assessment of prosthetic MR, particularly in paravalvular regurgitation; mild, moderate, and large leaks have been defined as widths of 1 to 2, 3 to 6, and ≥6 mm, respectively.<sup>154</sup> In a study involving 96 consecutive patients, 80% of patients with small (1-2 mm) regurgitation were asymptomatic, whereas 62% of those with large leaks were in New York Heart Association class III or IV.<sup>155</sup> As with native MR, the behavior of the jet in the left atrium, particularly significant swirling within the atrium, is specific for significant MR, as is the presence of retrograde systolic flow in one or more of the pulmonary veins. Likewise, the radius of the proximal flow convergence can be used in combination with recordings of MR velocity by CW Doppler to estimate effective regurgitant orifice area. However, because of the eccentric nature of many of these lesions, effective regurgitant orifice area is often overestimated; thus, the cutoff used to detect severe MR is ≥0.5 cm<sup>2</sup>.<sup>154</sup> More studies are needed to further substantiate these observations. The more concordant the parameters are in their normality or abnormality, the more confident is the evaluation of the severity of regurgitation.

## V. EVALUATION OF PROSTHETIC PULMONARY VALVES

### A. Prosthetic Pulmonary Valve Function

**1. Imaging Considerations.** Because the pulmonary valve is located anteriorly and superiorly, it is often difficult to fully visualize by either TTE or TEE. Typically, the pulmonary valve can be visualized using the RV outflow tract view from the parasternal window (modified

**Table 9** Transthoracic echocardiographic findings suggestive of significant prosthetic MR in mechanical valves with normal pressure half-time

Finding	Sensitivity	Specificity	Comments
Peak mitral velocity $\geq 1.9$ m/s*	90%	89%	Also consider high flow, PPM
$VTI_{PrMV}/VTI_{LVO} \geq 2.5^*$	89%	91%	Measurement errors increase in atrial fibrillation due to difficulty in matching cardiac cycles; also consider PPM
Mean gradient $\geq 5$ mmHg*	90%	70%	At physiologic heart rates; also consider high flow, PPM
Maximal TR jet velocity $> 3$ m/s*	80%	71%	Consider residual postoperative pulmonary hypertension or other causes
LV stroke volume derived by 2D or 3D imaging is $>30\%$ higher than systemic stroke volume by Doppler	Moderate sensitivity	Specific	Validation lacking; significant MR is suspected when LV function is normal or hyperdynamic and $VTI_{LVO}$ is $<16$ cm
Systolic flow convergence seen in the left ventricle toward the prosthesis	Low sensitivity	Specific	Validation lacking; technically challenging to detect readily

PrMV, Prosthetic mitral valve.

\*Data from Olmos et al.<sup>148</sup> When both peak velocity and VTI ratio are elevated with a normal pressure half-time, specificity is close to 100%.

**Table 10** Echocardiographic and Doppler criteria for severity of prosthetic MR using findings from TTE and TEE

Parameter	Mild	Moderate	Severe
<b>Structural parameters</b>			
LV size	Normal*	Normal or dilated	Usually dilated <sup>‡</sup>
Prosthetic valve <sup>  </sup>	Usually normal	Abnormal <sup>¶</sup>	Abnormal <sup>¶</sup>
<b>Doppler parameters</b>			
Color flow jet area <sup>   #</sup>	Small, central jet (usually $<4$ cm <sup>2</sup> or $<20\%$ of LA area)	Variable	Large central jet (usually $>8$ cm <sup>2</sup> or $>40\%$ of LA area) or variable size wall-impinging jet swirling in left atrium
Flow convergence**	None or minimal	Intermediate	Large
Jet density: CW Doppler <sup>  </sup>	Incomplete or faint	Dense	Dense
Jet contour: CW Doppler <sup>  </sup>	Parabolic	Usually parabolic	Early peaking, triangular
Pulmonary venous flow <sup>  </sup>	Systolic dominance <sup>§</sup>	Systolic blunting <sup>§</sup>	Systolic flow reversal <sup>†</sup>
<b>Quantitative parameters<sup>††</sup></b>			
VC width (cm) <sup>  </sup>	$<0.3$	0.3-0.59	$\geq 0.6$
R vol (mL/beat)	$<30$	30-59	$\geq 60$
RF (%)	$<30$	30-49	$\geq 50$
EROA (cm <sup>2</sup> )	$<0.20$	0.20-0.49	$\geq 0.50$

EROA, Effective regurgitant orifice area; RF, regurgitant fraction; R vol, regurgitant volume; VC, vena contracta.

\*LV size applied only to chronic lesions.

<sup>†</sup>Pulmonary venous systolic flow reversal is specific but not sensitive for severe MR.

<sup>‡</sup>In the absence of other etiologies of LV enlargement and acute MR.

<sup>§</sup>Unless other reasons for systolic blunting (eg, atrial fibrillation, elevated LA pressure).

<sup>||</sup>Parameter may be best evaluated or obtained with TEE, particularly in mechanical valves.

<sup>¶</sup>Abnormal mechanical valves, for example, immobile occluder (valvular regurgitation), dehiscence or rocking (paravalvular regurgitation); abnormal biologic valves, for example, leaflet thickening or prolapse (valvular), dehiscence or rocking (paravalvular regurgitation).

<sup>#</sup>At a Nyquist limit of 50 to 60 cm/s.

\*\*Minimal and large flow convergence defined as a flow convergence radius  $<0.4$  and  $\geq 0.9$  cm for central jets, respectively, with a baseline shift at a Nyquist limit of 40 cm/s; cutoffs for eccentric jets may be higher.

<sup>††</sup>These quantitative parameters are less well validated than in native MR.

from the parasternal short axis at the aortic level) or, in young patients, from the subcostal view. Unfortunately, the limited acoustic windows may limit the ability to fully assess prosthetic valve function.

Because the RV outflow is "funnel" shaped, it makes application of the continuity equation difficult; the RV outflow diameter changes dramatically as it approaches the pulmonary valve, making the accurate calculation of stroke volume in the RV outflow difficult. This compromises the accuracy of the calculation of EOA.

Branch pulmonary arterial stenosis is often associated with conditions that cause pulmonary valve stenosis. After replacement of the pulmonary valve, the branch stenosis may still be present and may interfere with the assessment of the replaced valve. For example, CW Doppler across the prosthetic valve may also record the peak velocity across the branch pulmonary artery stenosis. In this situation, PW Doppler may be a preferred method to assess the transprosthetic gradient rather than CW Doppler, especially because right-sided prosthetic valves often

have lower gradients. PW Doppler should be used only if aliasing does not occur.

Pulmonary valve replacements are sometimes inserted as pulmonary valve conduits. Although the valve may be functioning well without stenosis, the conduit may develop edge stenosis, again causing corruption of the CW Doppler signal. Thus, an elevated CW Doppler velocity should prompt further 2D visualization of the valve and conduit as well as PW Doppler interrogation to determine if branch pulmonary or conduit stenosis is present.

**2. Evaluation of Pulmonary Valve Function.** There is a paucity of data on prosthetic valves in the pulmonary position. Most of the data come from small sets of patients, mostly in the pediatric population with underlying congenital heart disease. Placement of the prosthetic valve and conduit in an anatomically aberrant position and the presence of RV structural abnormalities make standardization of velocities and gradients difficult. Evaluation of leaflet structure and mobility when feasible is helpful.

Suggested Doppler echocardiographic parameters for evaluation of prosthetic pulmonary valve function are presented in Table 11. Characterization of pulmonary valve prostheses is limited to pulmonary homograft valve conduits<sup>156</sup> or xenografts<sup>157</sup> in patients with congenital or systemic disease affecting the pulmonary valve or to cryopreserved pulmonary homografts in patients undergoing the Ross procedure.<sup>158-160</sup> The types of xenografts used are variable (Carpentier-Edwards, Hancock, Ionescu-Shiley), with resultant variability in normal values. Reported parameters are limited to Doppler velocities and gradients; only a few studies have derived EOA.<sup>161</sup>

Findings that raise the question of prosthetic valve dysfunction are listed in Table 12 (Figure 15). In general, normal homografts have a peak velocity < 2.5 m/s (mean gradient < 15 mm Hg), and normal xenografts have a peak velocity < 3.2 m/s (mean gradient < 20 mm Hg). Reports on mechanical prostheses in the pulmonary position are limited, making general recommendations difficult.<sup>157,162,163</sup> Another indirect approach to assess for the presence of valve stenosis that complements direct estimation of pulmonary valve gradient is to evaluate RV systolic pressure. If there is new RV systolic hypertension, prosthetic pulmonary stenosis should be considered and excluded. Direct visualization of the leaflets with full excursion and periodic, clinically indicated repeat echocardiography in the same patient for serial comparison remains the best method to rule out stenosis.

## B. Prosthetic Pulmonary Valve Regurgitation

There are limited data regarding the echocardiographic assessment of prosthetic PR. In patients with severe PR, volume overload of the right ventricle is present, with resultant flattening of the interventricular septum in diastole and resultant paradoxical motion.<sup>164,165</sup> With Doppler, the severity of regurgitation is usually subjectively graded, using an integrative approach similar to native PR,<sup>16</sup> with few modifications particularly relating to the eccentricity of some regurgitant lesions (Table 13). The advantages and limitations of each of these parameters have been previously discussed in detail.<sup>16</sup>

Using color Doppler, the severity of PR is graded on the basis of the components of the jet, including regurgitant jet width, vena contracta, and its penetration depth into the RV outflow.<sup>166-173</sup> Some authors have assessed the severity by jet width, in a manner analogous to that described for AR.<sup>174</sup> A thin narrow jet <25% of the pulmonary annulus is generally considered mild, and a wide jet >50% of the pulmonary annulus is severe. In paravalvular jets or other eccentric jets, however, these parameters become less reliable for assessment of PR severity and may underestimate the significance of the lesion. Rever-

**Table 11** Imaging and Doppler parameters in evaluation of prosthetic pulmonary valve function

Doppler echocardiography of the valve	Peak velocity/peak gradient Mean gradient DVI* EOA* Presence, location, and severity of regurgitation
Related cardiac chambers	RV size, function, and hypertrophy; RV systolic pressure <sup>†</sup>

\*Theoretically possible to calculate; few data exist.

†The RV dimensions are helpful only for patients who had normal right ventricles prior to valve replacement (ie, Ross procedure).

**Table 12** Findings suspicious for prosthetic pulmonary valve stenosis

Cusp or leaflet thickening or immobility
Narrowing of forward color map
Peak velocity through the prosthesis >3 m/s or >2 m/s through a homograft*
Increase in peak velocity on serial studies <sup>†</sup>
Impaired RV function or elevated RV systolic pressure

\*Suspicious but not diagnostic of stenosis.

†More reliable parameter.

sal of flow in the distal main pulmonary artery is indicative of at least moderate regurgitation.

Other supportive signs of PR severity include spectral Doppler recordings. A rapid deceleration rate of the jet velocity recording by CW or PW Doppler can be consistent with more severe regurgitation. However, this deceleration is also influenced by several factors, including RV diastolic properties.<sup>16</sup> In severe PR, a rapid equalization of RV and pulmonary artery pressures can occur before the end of diastole. In this case, a "to and fro" flow signal in the shape of a sine wave, with termination of flow in mid to late diastole, can be seen. The density of the PR Doppler signal also reflects the regurgitation severity.<sup>16</sup>

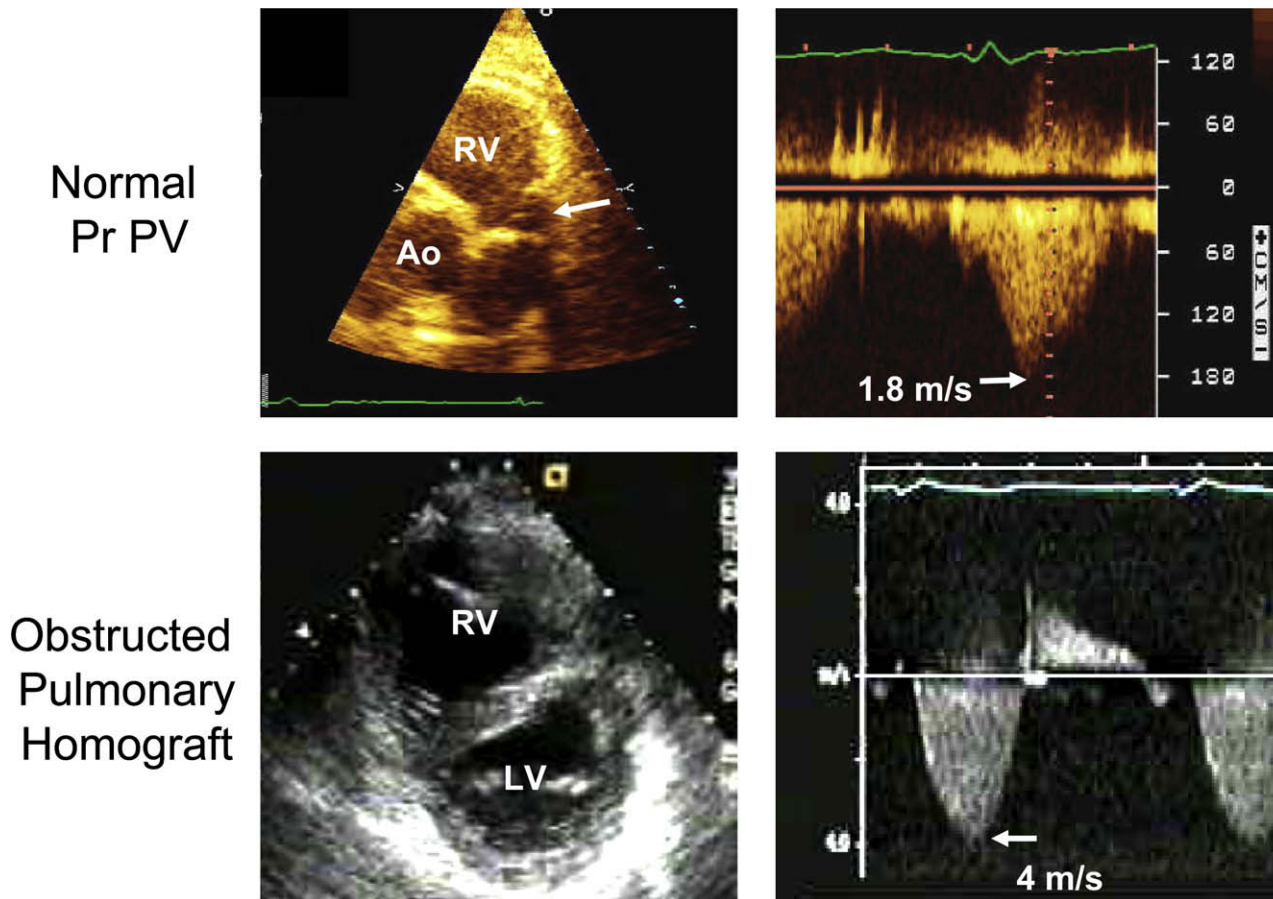
Quantitative parameters of regurgitation severity can be used in principle, with derivation of regurgitant volume and regurgitant fraction from the difference between pulmonary and systemic flow.<sup>16</sup> Although this measurement has not been validated for this purpose in PR, the concept is valid<sup>16</sup> but may be difficult to apply in practice. Because of the presence of a pulmonary prosthesis, pulmonary stroke volume determination is performed best in the RV outflow, just proximal to the valve, and compared with flow at the aortic or mitral annulus. In general, a regurgitant fraction <30% is usually mild, whereas a regurgitant fraction >50% is severe.<sup>170,175</sup> The RV outflow and pulmonary valve are anterior structures, offering a clear advantage of TTE in evaluating PR. Thus, although these structures can be visualized with TEE, the role of TEE in evaluating PR is limited.

## VI. EVALUATION OF PROSTHETIC TRICUSPID VALVES

### A. Prosthetic Tricuspid Valve Function

**1. Imaging Considerations.** The transthoracic approach allows a multitude of windows for visualization and flow interrogation of





**Figure 15** Examples of a normal prosthetic pulmonary valve and that of an obstructed pulmonary homograft showing dilatation of the right ventricle and a deformed septum. The obstructed homograft had a maximal gradient of 64 mm Hg.

prosthetic tricuspid valves. These include the parasternal, low parasternal, apical, and subcostal transducer positions. Forward flow hemodynamics are measured using CW Doppler from the various transducer positions to obtain the highest velocity measurements.

**2. Doppler Parameters of Tricuspid Prosthetic Valve Function.** The tricuspid prosthesis velocity varies not only with cycle length but also with respiration. Several cardiac cycles are therefore recorded by Doppler. A minimum of 5 cardiac cycles are averaged, whether the patient is in sinus rhythm or in atrial fibrillation; alternatively, measurements could be performed in midexpiratory apnea. Measurements include peak E velocity, peak A velocity (for patients in sinus rhythm), pressure half-time, mean gradient, and VTI. Similar to mitral prostheses, the average heart rate during the Doppler evaluation of the prosthesis should be noted in the report. When possible, and particularly when there is concern about valve obstruction, the prosthesis EOA can be calculated, although few data exist for the tricuspid valve. This is most often accomplished by dividing the stroke volume measured in the LVO tract by the prosthesis VTI, keeping in mind that the continuity principle is not in effect if there is more than mild TR or AR. If there is significant prosthetic TR, there is currently no convenient method for measuring the prosthesis EOA. In cases of significant AR without significant TR, the stroke volume can be measured at the level of the pulmonary annulus, because it represents the true systemic output. By analogy to mitral prostheses, it is likely that there is a cutoff for the DVI, the ratio of tricuspid pros-

thesis VTI divided by LVO tract VTI that, in combination with normal pressure half-time, will indicate a likelihood of significant tricuspid prosthesis regurgitation. However, to date, this cutoff has not been established in the literature. Of note, the EOA should not be calculated using the formula  $220/\text{pressure half-time}$ , because the constant of 220 has not been validated for tricuspid prostheses.

**3. Diagnosis of Prosthetic Tricuspid Valve Stenosis.** Echocardiographic and Doppler parameters that need to be obtained in the evaluation of prosthetic tricuspid valve function are listed in [Table 14](#). Prosthetic tricuspid obstruction may be obvious on imaging from thickening and reduced opening of the biologic cusps or reduced opening of the mechanical occluder. A narrowed inflow color map is a helpful corroborative sign. Obstruction is also suggested on CW Doppler by an E velocity  $> 1.7$  m/s, mean gradient  $> 6$  mm Hg, or pressure half-time  $> 230$  ms<sup>176,177</sup> ([Figure 16](#)). Indirect, nonspecific signs are an enlarged right atrium and engorged inferior vena cava.

Suggested cutoffs of Doppler parameters for considering tricuspid prosthesis dysfunction are shown in [Table 15](#). These cutoffs were selected using combined normal range data from the 3 pertinent published studies. These studies included a total of only 121 patients. Forty-seven patients had older-generation xenograft tricuspid prostheses, and 78 had mechanical prostheses with valve sizes ranging from 25 to 35 mm.<sup>176-178</sup> It is anticipated that these cutoffs may change as larger series for newer model tricuspid valve prostheses emerge.

**Table 13** Evaluation of severity of prosthetic pulmonary valve regurgitation

Parameter	Mild	Moderate	Severe
Valve structure	Usually normal	Abnormal or valve dehiscence	Abnormal or valve dehiscence
RV size	Normal*	Normal or dilated	Dilated <sup>‡</sup>
Jet size by color Doppler (central jets) <sup>  </sup>	Thin with a narrow origin; jet width $\leq$ 25% of pulmonary annulus	Intermediate; jet width 26%-50% of pulmonary annulus	Usually large, with a wide origin; jet width >50% of pulmonary annulus; may be brief in duration
Jet density by CW Doppler	Incomplete or faint	Dense	Dense
Jet deceleration rate by CW Doppler	Slow deceleration	Variable deceleration	Steep deceleration <sup>§</sup> , early termination of diastolic flow
Pulmonary systolic flow vs systemic flow by PW Doppler <sup>†</sup>	Slightly increased	Intermediate	Greatly increased
Diastolic flow reversal in the pulmonary artery	None	Present	Present

Adapted from Zoghbi et al.<sup>16</sup>

\*Unless other cause of RV dilatation exists, including residual postsurgical dilatation.

†Cutoff values for regurgitant volume and fraction are not well validated.

‡Unless there are other reasons for RV enlargement. Acute PR is an exception. RV volume overload is usually accompanied with typical paradoxical septal motion.

§Steep deceleration is not specific for severe PR.

||At a Nyquist limit of 50 to 60 cm/s; parameter applies to central jets and not eccentric jets.

For the 121 patients in the currently available series, the mean tricuspid E velocity was  $1.3 \pm 0.2$  m/s, with all patients having E velocities of  $\leq 1.7$  m/s. For patients in sinus rhythm, the mean A velocity was  $1.0 \pm 0.3$  m/s. The mean gradient for patients with normal St Jude Medical tricuspid prostheses was  $2.7 \pm 1.1$  mm Hg. It was  $3.2 \pm 1.1$  mm Hg for patients with normal xenograft tricuspid prostheses and  $3.1 \pm 0.8$  mm Hg for those with normal caged-ball tricuspid prostheses. All 121 patients with normal tricuspid prostheses had mean gradients  $\leq 5.5$  mm Hg.

The mean pressure half-times for patients with normal xenograft prostheses ( $146 \pm 39$  ms) and normal caged-ball prostheses ( $144 \pm 46$  ms) were greater than that for patients with normal St Jude Medical tricuspid prostheses ( $108 \pm 32$  ms). All but 1 of these 121 patients had a pressure half-time  $< 200$  ms (the single exception was a patient with a normal tricuspid caged-ball prosthesis with a pressure half-time of 230 ms).

To date, there are no data from a large series of patients with normal tricuspid prostheses that include measurement of EOA by the continuity equation or of the DVI ( $VTI_{PrTV}/VTI_{LVO}$ ) akin to that of prosthetic mitral valves.

## B. Prosthetic TR

Although several studies have addressed the issue of structural failure in tricuspid bioprostheses, the focus has been placed on increased gradients, with little mention of TR. Therefore, the present guidelines are based on expert recommendation rather than on data from clinical studies. The suggested criteria for assessing severity of prosthetic TR are proposed to be similar to those for native tricuspid valves,<sup>16</sup> with few modifications (Table 16).

**1. Imaging Considerations.** A combination of parasternal, apical, and subcostal views is needed for the optimal assessment of tricuspid valve function and cardiac adaptation. In significant TR, right atrial and RV dilatation with diastolic septal flattening occurs in association with dilatation of the inferior vena cava and hepatic veins. The size of the cardiac chambers, however, should be interpreted with caution, because many if not all of these adaptations could be due to the underlying pathology and changes that occurred before tricuspid

**Table 14** Echocardiographic and Doppler parameters in evaluation of prosthetic tricuspid valve function

Doppler echocardiography of the valve	Peak early velocity Mean gradient Heart rate at time of Doppler assessment Pressure half-time $VTI_{PrTV}/VTI_{LVO}$ * EOA* Presence, location, and severity of TR
Related cardiac chambers, inferior vena cava and hepatic veins	RV size and function Right atrial size Size of inferior vena cava and response to inspiration Hepatic vein flow pattern

*PrTV*, Prosthetic tricuspid valve.

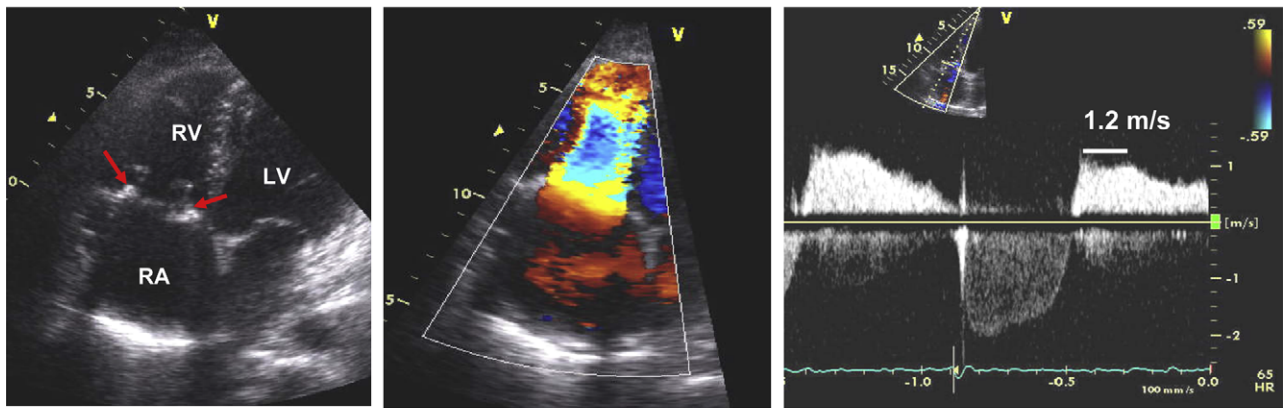
\*Feasible measurements of valve function, similar to mitral prostheses, but no large series to date.

valve implantation. The absence of these findings, however, argues against severe TR.

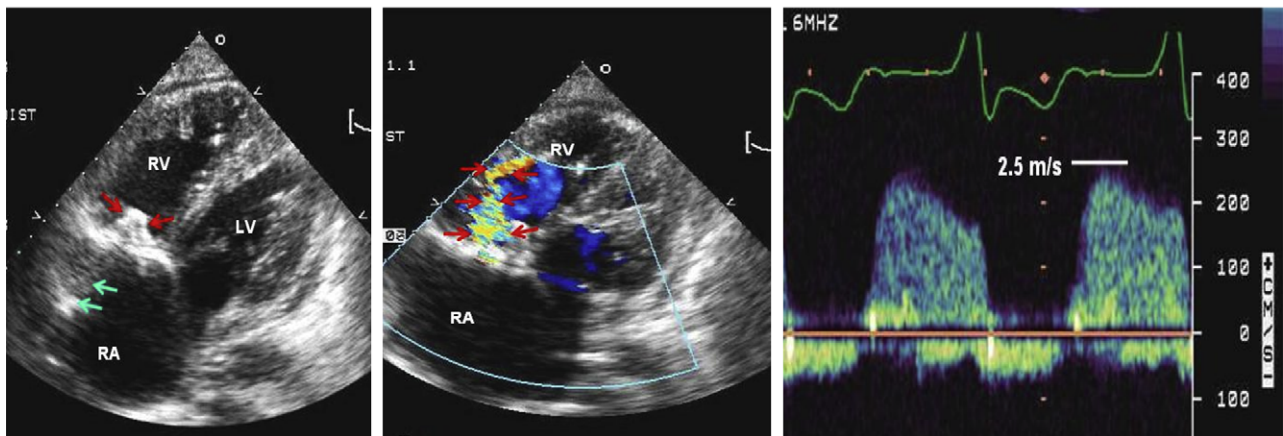
**2. Doppler Parameters of Tricuspid Prosthetic Valve Regurgitation.** TTE with Doppler is a good screening test for TR but is limited by attenuation, particularly in patients with mechanical valves. The best views may be the RV inflow or subcostal views. Quantitative color Doppler techniques used in native valvular regurgitation have a limited role in prosthetic regurgitation. However they are part of the global examination of suspected severe TR. For instance, a large flow convergence or vena contracta usually means severe TR, and its location may help in assessing the origin of the regurgitation.

For spectral Doppler, screening with CW Doppler is better than PW Doppler. Both imaging and nonimaging CW Doppler probes should be used, the latter having a superior penetration. Clues from spectral CW Doppler that suggest severe regurgitation include a dense spectral recording with a triangular, early peaking velocity as well as elevated peak and mean tricuspid diastolic pressure gradients.

### Normal Tricuspid Prosthetic Valve



### Tricuspid Stenosis



**Figure 16** Transthoracic echocardiographic and Doppler images in a patient with normal prosthetic tricuspid valve and another with prosthetic stenosis. The case with normal prosthetic valve function had mild TR and a large central inflow jet in diastole. The patient with tricuspid valve stenosis had an eccentric narrow jet with an elevated velocity and mean gradient.

**Table 15** Doppler parameters of prosthetic tricuspid valve function

	Consider valve stenosis*
Peak velocity <sup>†</sup>	>1.7 m/s
Mean gradient <sup>†</sup>	≥6 mm Hg
Pressure half-time	≥230 ms
EOA and VTI <sub>PrTV</sub> /VTI <sub>LVO</sub>	No data yet available for tricuspid prostheses

PrTV, Prosthetic tricuspid valve.

\*Because of respiratory variation, average ≥5 cycles.

†May be increased also with valvular regurgitation.

The presence of a prosthetic valve with its inherent restriction to flow influences the flow pattern in the hepatic veins. Even when the prosthetic valve functions normally, some degree of systolic blunting can be expected. Marked systolic blunting is more sensitive for significant TR but is not specific and can be seen in patients with elevated central venous pressure of any etiology or in patients with atrial fibrillation. In general, holosystolic reversal of hepatic venous flow indicates severe TR.

**3. TEE for Prosthetic Tricuspid Valves.** TEE should be considered for all patients with clinical and/or transthoracic echocardiographic evidence of tricuspid prosthesis obstruction. The study focuses on delineating the motion of prosthetic leaflets or occluder and on identification of masses attached to the prosthesis. Imaging with TEE, however, may be technically suboptimal because of shadowing of the prosthesis from the interatrial septum or cardiac crux. Doppler angulation with the transesophageal echocardiographic approach may not be as favorable as with TTE, with a resultant underestimation of the velocity and gradient across the valve.

TEE should also be considered for patients with suspected prosthetic TR. The examination focuses on identifying the jet or jets as paravalvular or transvalvular. Semiquantitation of severity is performed by identifying the extent to which the color jet of regurgitation fills the right atrium and, when possible, evaluation of hepatic vein flow using a transgastric approach. If a zone of flow convergence can be identified on the ventricular side of the prosthesis and is not significantly distorted by adjacent structures, TR can be quantitated according to the proximal isovelocity surface area method.<sup>16</sup> TEE should be considered as an adjunct to TTE for all patients with high clinical suspicion of endocarditis. Here the examination would focus not only on identification of vegetations but also on evidence of

**Table 16** Echocardiographic and Doppler parameters used in grading severity of prosthetic tricuspid valve regurgitation

Parameter	Mild	Moderate	Severe
Valve structure	Usually normal	Abnormal or valve dehiscence	Abnormal or valve dehiscence
Jet area by color Doppler, central jets only (cm <sup>2</sup> )	<5	5-10	>10
VC width (cm)*	Not defined	Not defined, but <0.7	>0.7
Jet density and contour by CW Doppler	Incomplete or faint, parabolic	Dense, variable contour	Dense with early peaking
Doppler systolic hepatic flow	Normal or blunted	Blunted	Holosystolic reversal
Right atrium, right ventricle, IVC	Normal†	Dilated	Markedly dilated

IVC, Inferior vena cava; VC, vena contracta.

Adapted from Zoghbi et al.<sup>16</sup>

\*For a valvular TR jet, extrapolated from native TR; unknown cutoffs for paravalvular TR.

†If no other reason for dilatation.

perivalvular extension of the infection such as ring abscess, valve dehiscence, or fistula formation.

## VII. ECHOCARDIOGRAPHIC EVALUATION OF PROSTHETIC VALVES IN THE PEDIATRIC POPULATION

Although the prevalence of prosthetic valves is much less common in the pediatric population, their presence has obvious implications for individual patients. To date, a paucity of published information exists concerning the appropriate evaluation of prosthetic valves in the young.<sup>179-181</sup> Equally important is the lack of studies detailing normal Doppler echocardiographic values across prosthetic valves in the pediatric population.<sup>179</sup> Hence, to date, much of the information is gleaned from the evaluation of adult patients with prosthetic valves. Fortunately, many of the important principles concerning hemodynamics, echocardiographic imaging, and other considerations are similar. Thus, the evaluation of prosthetic valve function, as discussed earlier, can and should be readily applied to the pediatric population. The following will not reiterate the principles of echocardiographic evaluation already discussed but will highlight the differences particularly germane to the pediatric population.

### A. Prosthetic Valves Are Uncommon in Pediatrics

Prosthetic valve placement is naturally avoided in pediatric patients, the most important aspect being that growth of the patient will lead to inevitable PPM. Additionally, tissue valves, especially when placed in the systemic circulation, can result in rapid calcification and subsequent degeneration. Thus, before the early adult age group, metallic valves are generally used in the systemic circulation, with the inherent difficulties of anticoagulation in the pediatric age group. This had led to widespread use of the Ross procedure, especially for aortic valve replacement. The translocated pulmonary valve and root does not require anticoagulation, and studies have documented tissue growth, commensurate with that of the patient. However, the Ross procedure is associated with the need for early percutaneous or surgical interventions either for pulmonary conduit stenosis or regurgitation. Additionally, aortic root and annular dilation can occur, with associated progressive AR.

### B. Aspects of Pediatric Congenital Heart Disease Alter the Standard Approach to Echocardiographic Prosthetic Valve Evaluation

Much emphasis has been placed on anatomic imaging of prosthetic valves in adult patients. However, even in young children, the echo-

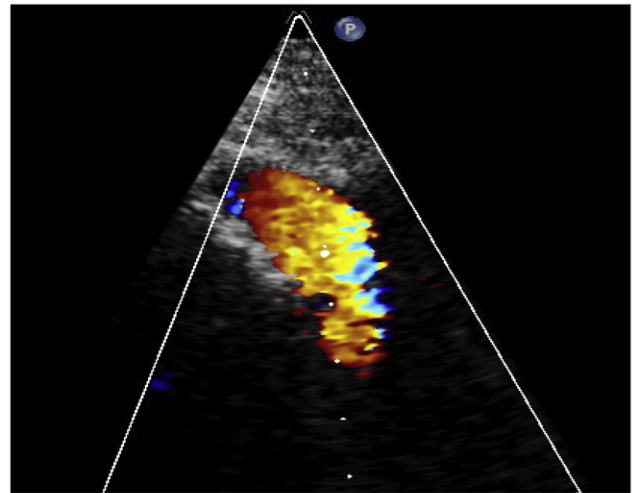
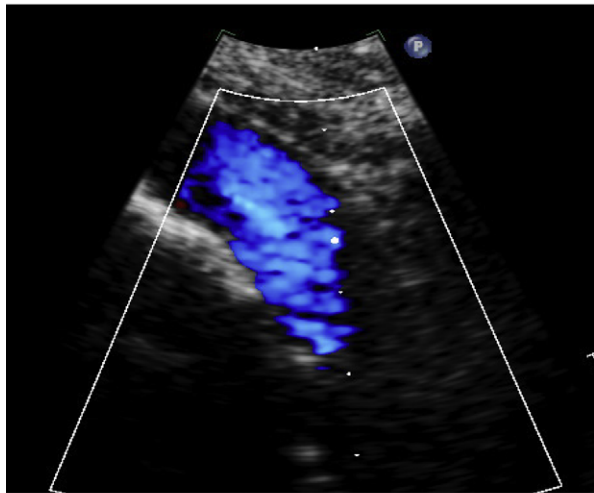
cardiographic images may be suboptimal because of multiple surgeries, chest wall deformities, and so on. In particular, imaging of the valve leaflets may be difficult to perform by 2D imaging. This is related in part to the low frame rates, in relation to higher heart rates in pediatric patients. M-mode echocardiography, with much higher frame rates, may yield some improvement in examining leaflet motion. Often, standard fluoroscopy is also used to evaluate metallic leaflet motion and position.

A significant contributor to the difficulty in echocardiographic evaluation of prosthetic valves in the pediatric age group is the coexistence of multiple levels of obstruction. For example, patients with Shone's syndrome may have supralvalvar mitral ring, parachute mitral valve, subaortic stenosis, bicuspid aortic valve, and aortic coarctation. If a prosthetic valve is placed in the aortic position, associated subaortic stenosis will not allow application of the continuity equation to determine EOA. Additionally, associated coarctation may directly affect the pressure gradients across a prosthetic aortic valve. On the right side of the heart, multiple levels of obstruction across a conduit, especially if stenosis extends to the right or left pulmonary artery, will directly affect pressure measurements across the valve.

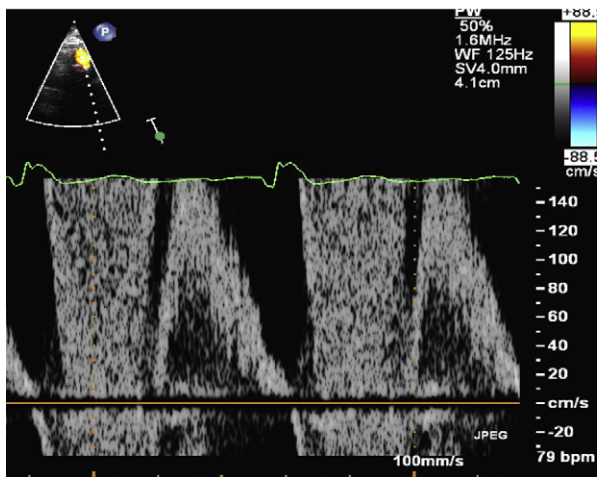
Another example of the differences between pediatric and adult patients relates to placement of prosthetic valves in the supra-annular position. In the rare event that an infant with a small mitral valve annulus requires placement of a prosthetic mitral valve, surgeons may choose to place the valve in the supra-annular position. This is associated with a significant elevation in LA mean pressure related to high "v" waves, even in the absence of valve dysfunction.<sup>182</sup> Doppler recording in this situation will show an elevated transmitral E velocity and mean pressure gradient. This phenomenon has been attributed to alterations in atrial compliance.

The use of pulmonary artery conduits after repair of a multitude of congenital heart defects is much more common in pediatric patients (Figure 17). This includes neonatal repair of truncus arteriosus, tetralogy of Fallot with pulmonary atresia, and Rastelli operation for transposition of the great arteries with LVO tract obstruction. With advances in surgical techniques, RV-to-pulmonary artery conduits are being placed for the Sano revision of the stage I operation for hypoplastic left-heart syndrome or for the Yasui surgery for interrupted aortic arch. The increasing use of the Ross procedure in pediatric patients of all ages has resulted in increased numbers of these conduits. RV-to-pulmonary artery conduits are now being placed with increasing frequency in adolescents and young adults who have severe PR after primary repair of tetralogy of Fallot. Early reports had demonstrated that Doppler can accurately measure the gradients across RV-to-pulmonary conduits. Doppler maximal instantaneous gradients may closely approximate those obtained at catheterization

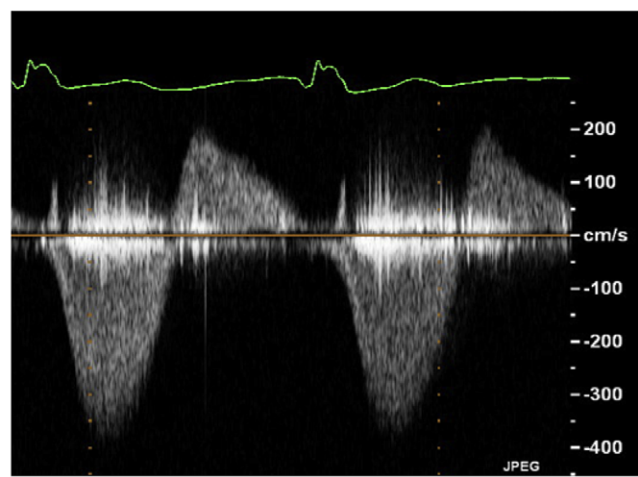
## RV- PA Conduit



### Pulsed Doppler



### CW Doppler



**Figure 17** Two-dimensional echocardiographic evaluation of a RV-to-pulmonary artery homograft valve conduit after repair of a truncus arteriosus, interrogated from the left parasternal view. Forward flow (*blue*) and retrograde flow (*red*) of pulmonary regurgitation is seen. Pulsed Doppler shows aliasing signals of stenosis and a retrograde signal of regurgitation at the level of the valve. CW Doppler signal from the valve conduit shows significant stenosis and regurgitation.

when there is a discrete region of narrowing, such as calcified valve or discrete obstruction at the insertion site of the proximal conduit to the right ventricle. However, in other situations, Doppler may underestimate the severity of disease. This most often occurs when significant stenosis occurs at the conduit-to-pulmonary artery anastomosis. The jet lesions in these conduits are quite eccentric and difficult to interrogate, even with dedicated CW Doppler probes. However, in the presence of associated peripheral pulmonary stenosis, CW Doppler interrogation of these areas of obstruction may obfuscate the measurement of proximal obstruction. Moreover, these velocities often exceed the gradients at catheterization. In such situations, evaluation of the TR jet to assess RV pressure cannot be overemphasized.

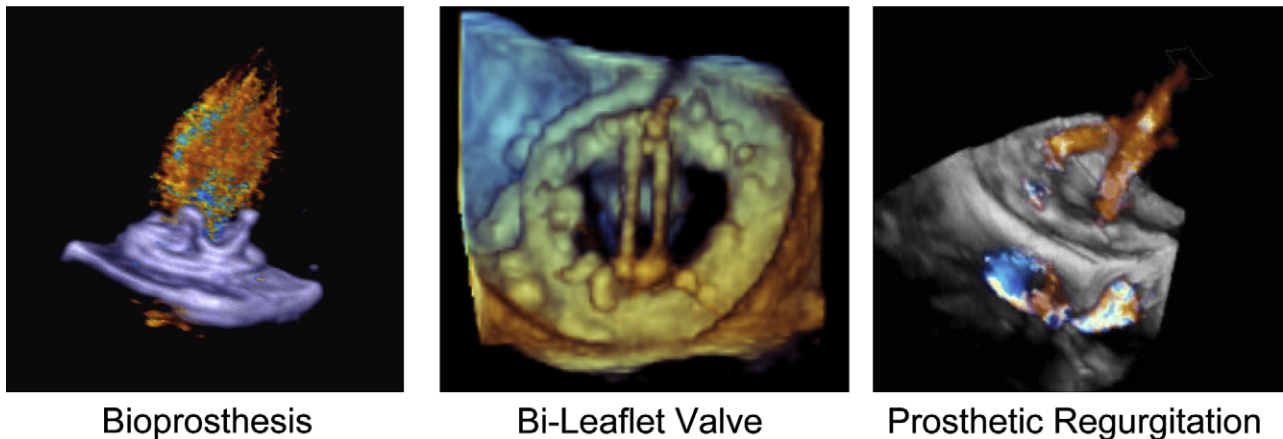
### C. Importance of PPM in Pediatrics

Mitral and or aortic valve stenosis in infants or children is associated with annular hypoplasia, often resulting in placement of a smaller prosthetic valve than would be appropriate for the patient's size.

This problem is magnified with pediatric patients' growth. Surgeons may attempt to enlarge the aortic annular region by either a Konno or Manugian procedure, yet still a suboptimal sized valve will be placed. When high velocities are interrogated across prosthetic valves in young patients, the algorithms as presented in this document should be applied. The cutoff values for the peak and mean velocities and gradients must be considered in the context of the patient's size; PPM and pressure recovery need to be taken into account.

A very significant contributor to progressive valvar obstruction in the pediatric age group is pannus formation. Moreover, severe left-sided obstruction is often associated with endocardial fibroelastosis, a fibrous scarring that may incite subsequent pannus formation.<sup>183</sup> The obstructive fibrous tissue may be difficult to image by standard transthoracic imaging. TEE may result in improved imaging, but the pannus may be difficult to differentiate from the actual sewing ring. On the other hand, thrombus formation may be an acute cause of a sudden increase in pressure gradients and/or development of

### 3 D Echocardiography



**Figure 18** Examples of 3D echocardiography and Doppler images of a bioprosthetic valve (*left*), bileaflet mechanical valve in the mitral position from the LA view (Video 17, [video clips online](#)), and a prosthetic valve with regurgitation.

regurgitation. The valve may be fixed in position, culminating in prosthetic valve stenosis and regurgitation, which would be unlikely to be seen with either pannus formation or PPM.

#### D. Potential Pitfalls in the Measurement of Prosthetic Valve EOA in Pediatrics

The evaluation of prosthetic valve function often requires measurement of EOA. In pediatric patients, associated shunts will affect flow and hence pressure gradients. This includes the presence of an atrial septal defect, which potentially decreases flow across a prosthetic mitral and or aortic valve, or a patent ductus arteriosus, which may increase flow. Equally important, PPM necessitates calculation of indexed EOA.

To date, EOA by the continuity equation has not been readily applied in the pediatric population. As mentioned, the most difficult aspect for accurate derivation of EOA has been the determination of the preprosthetic valve VTI and area. Several factors make this measurement more difficult in pediatric patients. First, the area is presumed to be circular. This may not be true in patients with associated LVO tract or RV outflow tract disease. Second, for area measurement, the radius is raised to the second power, and thus even small discrepancies in diameter measurement will result in large errors in area calculation. This potential error will be magnified in smaller patients. Third, the preobstruction flow velocity pattern will not be laminar in pediatric patients with subaortic or subpulmonary stenosis. Fourth, translational motion of the heart impedes the ability to place the Doppler sample volume precisely in the area of the preprosthetic valve. This problem again seems to be more evident in younger pediatric patients.

A few studies in small numbers of patients have reported on the optimal manner to determine the presence of PPM in pediatric patients. One study examined 32 infants and children with placement of prosthetic St Jude Medical or Carbomedics valves in the mitral position. The Doppler measurement that correlated best to the manufacturer-derived EOA was the peak Doppler velocity, not the EOA. Potentially, some of the problems of the calculation of EOA may be overcome by use of the DVI. The index has been related to severity of disease in adult patients, but application of this index has not been reported in pediatric patients. Despite the potential pitfalls,

attempts to use EOA and/or DVI should become part of the standard evaluation of pediatric patients with prosthetic valves.

#### E. Evaluation of Corresponding Atrial and Ventricular Size and Function

Equally important to the evaluation of prosthetic valve function is the analysis of the corresponding effects on atrial and ventricular size and function. In pediatric patients, normative values for 2D echocardiographic evaluations for LV size and function, using z-score values, have been developed. These values can be tracked over time, therefore incorporating changes relative to growth and development. Unfortunately, echocardiographic normative values for RV volume and mass or left or right atrial volumes have not been established but are under way. Indices of ventricular systolic performance should be used to account for loading conditions. Such echocardiographic parameters include indices of wall stress to velocity of circumferential fiber shortening or wall stress to fractional shortening. Although echocardiographic evaluation of prosthetic valve function includes indices of ventricular systolic performance, evaluation of ventricular diastolic dysfunction should also be explored.

#### F. The Need for More Research in the Pediatric Population

Perhaps the most difficult aspect concerning the evaluation of prosthetic valves in pediatric patients is the paucity of published data. The deleterious outcomes related to PPM in adults have been demonstrated, but the effect of PPM is unknown in pediatric patients. Few studies have reported on the outcomes of pediatric patients with prosthetic valves. Therefore, pediatric cardiologists rely on guidelines established for adult patients. The importance for additional research and analysis in a large number of pediatric patients cannot be overemphasized.

### VIII. CONCLUSIONS AND FUTURE DIRECTIONS

Echocardiography with Doppler is currently the modality of choice for evaluation and management of prosthetic heart valves as well as native cardiac valves. Imaging of the prosthesis in addition to the related cardiac chambers is crucial in evaluating overall prosthetic valve function and assessment of the extent of reverse remodeling of the

cardiac chambers after surgery. Doppler interrogation with color and spectral modalities plays a central role in evaluating prosthetic valve function and related complications because of limitations of imaging alone, particularly in mechanical valves. In patients with suspected prosthetic valvular dysfunction, TEE is frequently needed for identification of the mechanism of obstruction or regurgitation, particularly in mechanical valves.

In general, evaluation of prosthetic valve function is more challenging, on the basis of the variability of inherent mild obstruction observed with the wide range of prosthetic valve types and sizes. Thus, the cardiac history plays a major role in the echocardiographic evaluation by documenting the type and size of the inserted valve or conduit. Serial comparison with a baseline postoperative study is also essential in facilitating accurate assessment of valve function. More research is needed on normative values of various parameters of valvular function and their prognostic impact in the pediatric population.

Recent advances in real-time 3D imaging from the transthoracic and, more important, from the transesophageal approach offer an important additional dimension in the echocardiographic evaluation of prosthetic valve function<sup>184</sup> (Figure 18). Three-dimensional imaging provides a powerful tool to image, for the first time with ultrasound, the motion of the entire valve apparatus and its annulus. This will undoubtedly enhance our appraisal of prosthetic valve function and the differentiation of PPM from valvular obstruction in the same setting. The incorporation of color Doppler will enhance measurements of flow convergence, vena contracta, and the extent of the jet in the receiving chamber for improved quantitation of prosthetic valvular regurgitation. Furthermore, preliminary experience<sup>185</sup> has shown that future applications of real-time 3D TEE will most likely include guidance of percutaneous interventions in high-risk patients with paravalvular regurgitation.

#### Supplementary data

Supplementary data associated with this article can be found in the online version, at doi:10.1016/j.echo.2009.07.013

#### REFERENCES

1. Bonow RO, Carabello BA, Kanu C, et al. ACC/AHA 2006 guidelines for the management of patients with valvular heart disease: a report of the American College of Cardiology/American Heart Association Task Force on Practice Guidelines (Writing Committee to Revise the 1998 Guidelines for the Management of Patients With Valvular Heart Disease): developed in collaboration with the Society of Cardiovascular Anesthesiologists: endorsed by the Society for Cardiovascular Angiography and Interventions and the Society of Thoracic Surgeons. *Circulation* 2006;114:e84-231.
2. Jamieson WR. Current and advanced prostheses for cardiac valvular replacement and reconstruction surgery. *Surg Technol Int* 2002;10:121-49.
3. Christakis GT, Buth KJ, Goldman BS, et al. Inaccurate and misleading valve sizing: a proposed standard for valve size nomenclature. *Ann Thorac Surg* 1998;66:1198-203.
4. Chambers JB, Oo L, Narracott A, Lawford PM, Blauth CI. Nominal size in six bileaflet mechanical aortic valves: a comparison of orifice size and biologic equivalence. *J Thorac Cardiovasc Surg* 2003;125:1388-93.
5. Grube E, Schuler G, Buellesfeld L, et al. Percutaneous aortic valve replacement for severe aortic stenosis in high-risk patients using the second- and current third-generation self-expanding CoreValve prosthesis: device success and 30-day clinical outcome. *J Am Coll Cardiol* 2007;50:69-76.
6. Khambadkone S, Coats L, Taylor A, et al. Percutaneous pulmonary valve implantation in humans: results in 59 consecutive patients. *Circulation* 2005;112:1189-97.
7. Webb JG, Chandavimol M, Thompson CR, et al. Percutaneous aortic valve implantation retrograde from the femoral artery. *Circulation* 2006;113:842-50.
8. Moss R, Ivens E, Pasupati S, et al. Role of echocardiography in percutaneous aortic valve implantation. *J Am Coll Cardiol Cardiovasc Imaging* 2008;1:15-24.
9. Gammie JS, Brown JW, Brown JM, et al. Aortic valve bypass for the high-risk patient with aortic stenosis. *Ann Thorac Surg* 2006;81:1605-10.
10. Lang RM, Bierig M, Devereux RB, et al. Recommendations for chamber quantification: a report from the American Society of Echocardiography's Guidelines and Standards Committee and the Chamber Quantification Writing Group, developed in conjunction with the European Association of Echocardiography, a branch of the European Society of Cardiology. *J Am Soc Echocardiogr* 2005;18:1440-63.
11. Alam M, Goldstein S, Lakier JB. Echocardiographic changes in the thickness of porcine valves with time. *Chest* 1981;79:663-8.
12. Effron MK, Popp RL. Two-dimensional echocardiographic assessment of bioprosthetic valve dysfunction and infective endocarditis. *J Am Coll Cardiol* 1983;2:597-606.
13. Del Rizzo DF, Goldman BS, Christakis GT, David TE. Hemodynamic benefits of the Toronto stentless valve. *J Thorac Cardiovasc Surg* 1996;112:1431-45.
14. Walther T, Autschbach R, Falk V, et al. The stentless Toronto SPV bioprosthesis for aortic valve replacement. *Cardiovasc Surg* 1996;4:536-42.
15. Quinones MA, Otto CM, Stoddard M, Waggoner A, Zoghbi WA. Recommendations for quantification of Doppler echocardiography: a report from the Doppler Quantification Task Force of the Nomenclature and Standards Committee of the American Society of Echocardiography. *J Am Soc Echocardiogr* 2002;15:167-84.
16. Zoghbi WA, Enriquez-Sarano M, Foster E, et al. Recommendations for evaluation of the severity of native valvular regurgitation with two-dimensional and Doppler echocardiography. *J Am Soc Echocardiogr* 2003;16:777-802.
17. Burstow DJ, Nishimura RA, Bailey KR, et al. Continuous wave Doppler echocardiographic measurement of prosthetic valve gradients. A simultaneous Doppler-catheter correlative study. *Circulation* 1989;80:504-14.
18. Baumgartner H, Khan S, DeRobertis M, Czer L, Maurer G. Discrepancies between Doppler and catheter gradients in aortic prosthetic valves in vitro. A manifestation of localized gradients and pressure recovery. *Circulation* 1990;82:1467-75.
19. Baumgartner H, Khan S, DeRobertis M, Czer L, Maurer G. Effect of prosthetic aortic valve design on the Doppler-catheter gradient correlation: an in vitro study of normal St. Jude, Medtronic-Hall, Starr-Edwards and Hancock valves. *J Am Coll Cardiol* 1992;19:324-32.
20. Baumgartner H, Schima H, Tulzer G, Kuhn P. Effect of stenosis geometry on the Doppler-catheter gradient relation in vitro: a manifestation of pressure recovery. *J Am Coll Cardiol* 1993;21:1018-25.
21. Baumgartner H, Stefenelli T, Niederberger J, Schima H, Maurer G. "Overestimation" of catheter gradients by Doppler ultrasound in patients with aortic stenosis: a predictable manifestation of pressure recovery. *J Am Coll Cardiol* 1999;33:1655-61.
22. Chafizadeh ER, Zoghbi WA. Doppler echocardiographic assessment of the St. Jude Medical prosthetic valve in the aortic position using the continuity equation. *Circulation* 1991;83:213-23.
23. Assey ME, Zile MR, Usher BW, Karavan MP, Carabello BA. Effect of catheter positioning on the variability of measured gradient in aortic stenosis. *Cathet Cardiovasc Diagn* 1993;30:287-92.
24. Chambers JB, Spriggs DC, Cochrane T, et al. Continuity equation and Gorlin formula compared with directly observed orifice area in native and prosthetic aortic valves. *Br Heart J* 1992;67:193-9.
25. Garcia D, Pibarot P, Dumesnil JG, Sakr F, Durand LG. Assessment of aortic valve stenosis severity: a new index based on the energy loss concept. *Circulation* 2000;101:765-71.
26. Heinrich RS, Fontaine AA, Grimes RY, et al. Experimental analysis of fluid mechanical energy losses in aortic valve stenosis: importance of pressure recovery. *Ann Biomed Eng* 1996;24:685-94.

27. Heinrich RS, Marcus RH, Ensley AE, Gibson DE, Yoganathan AP. Valve orifice area alone is an insufficient index of aortic stenosis severity: effects of the proximal and distal geometry on transaortic energy loss. *J Heart Valve Dis* 1999;8:509-15.
28. Levine RA, Jimoh A, Cape EG, McMillan S, Yoganathan AP, Weyman AE. Pressure recovery distal to a stenosis: potential cause of gradient "overestimation" by Doppler echocardiography. *J Am Coll Cardiol* 1989;13:706-15.
29. Levine RA, Cape EG, Yoganathan AP. Pressure recovery distal to stenoses: expanding clinical applications of engineering principles. *J Am Coll Cardiol* 1993;21:1026-8.
30. Levine RA, Schwammenthal E. Stenosis is in the eye of the observer: impact of pressure recovery on assessing aortic valve area. *J Am Coll Cardiol* 2003;41:443-5.
31. Niederberger J, Schima H, Maurer G, Baumgartner H. Importance of pressure recovery for the assessment of aortic stenosis by Doppler ultrasound. Role of aortic size, aortic valve area, and direction of the stenotic jet in vitro. *Circulation* 1996;94:1934-40.
32. Marcus RH, Heinrich RS, Bednarz J, et al. Assessment of small-diameter aortic mechanical prostheses: physiological relevance of the Doppler gradient, utility of flow augmentation, and limitations of orifice area estimation. *Circulation* 1998;98:866-72.
33. Dumesnil JG, Honos GN, Lemieux M, Beauchemin J. Validation and applications of indexed aortic prosthetic valve areas calculated by Doppler echocardiography. *J Am Coll Cardiol* 1990;16:637-43.
34. Dumesnil JG, Honos GN, Lemieux M, Beauchemin J. Validation and applications of mitral prosthetic valvular areas calculated by Doppler echocardiography. *Am J Cardiol* 1990;65:1443-8.
35. Dumesnil JG, Yoganathan AP. Valve prosthesis hemodynamics and the problem of high transprosthetic pressure gradients. *Eur J Cardiothorac Surg* 1992;6(suppl):S34-7.
36. Pibarot P, Dumesnil JG. Hemodynamic and clinical impact of prosthesis-patient mismatch in the aortic valve position and its prevention. *J Am Coll Cardiol* 2000;36:1131-41.
37. Hanayama N, Christakis GT, Mallidi HR, et al. Patient prosthesis mismatch is rare after aortic valve replacement: valve size may be irrelevant. *Ann Thorac Surg* 2002;73:1822-9.
38. Blais C, Dumesnil JG, Baillet R, Simard S, Doyle D, Pibarot P. Impact of valve prosthesis-patient mismatch on short-term mortality after aortic valve replacement. *Circulation* 2003;108:983-8.
39. Milano AD, De CM, Mecozzi G, et al. Clinical outcome in patients with 19-mm and 21-mm St. Jude aortic prostheses: comparison at long-term follow-up. *Ann Thorac Surg* 2002;73:37-43.
40. Tasca G, Brunelli F, Cirillo M, et al. Impact of valve prosthesis-patient mismatch on left ventricular mass regression following aortic valve replacement. *Ann Thorac Surg* 2005;79:505-10.
41. Blackstone EH, Cosgrove DM, Jamieson WR, et al. Prosthesis size and long-term survival after aortic valve replacement. *J Thorac Cardiovasc Surg* 2003;126:783-96.
42. Koch CG, Khandwala F, Estafanos FG, Loop FD, Blackstone EH. Impact of prosthesis-patient size on functional recovery after aortic valve replacement. *Circulation* 2005;111:3221-9.
43. Dumesnil JG, Pibarot P. Prosthesis-patient mismatch and clinical outcomes: the evidence continues to accumulate. *J Thorac Cardiovasc Surg* 2006;131:952-5.
44. Pibarot P, Dumesnil JG. Prosthesis-patient mismatch: definition, clinical impact, and prevention. *Heart* 2006;92:1022-9.
45. Mohty D, Malouf JF, Girard SE, et al. Impact of prosthesis-patient mismatch on long-term survival in patients with small St Jude Medical mechanical prostheses in the aortic position. *Circulation* 2006;113:420-6.
46. Ruel M, Al-Faleh H, Kulik A, Chan KL, Mesana TG, Burwash IG. Prosthesis-patient mismatch after aortic valve replacement predominantly affects patients with preexisting left ventricular dysfunction: effect on survival, freedom from heart failure, and left ventricular mass regression. *J Thorac Cardiovasc Surg* 2006;131:1036-44.
47. Pibarot P, Dumesnil JG, Lemieux M, Cartier P, Metras J, Durand LG. Impact of prosthesis-patient mismatch on hemodynamic and symptomatic status, morbidity and mortality after aortic valve replacement with a bio-prosthetic heart valve. *J Heart Valve Dis* 1998;7:211-8.
48. Castro LJ, Arcidi JM Jr, Fisher AL, Gaudiani VA. Routine enlargement of the small aortic root: a preventive strategy to minimize mismatch. *Ann Thorac Surg* 2002;74:31-6.
49. Pibarot P, Dumesnil JG, Cartier PC, Metras J, Lemieux MD. Patient-prosthesis mismatch can be predicted at the time of operation. *Ann Thorac Surg* 2001;71:S265-8.
50. Rahimtoola SH, Murphy E. Valve prosthesis-patient mismatch. A long-term sequela. *Br Heart J* 1981;45:331-5.
51. Lam BK, Chan V, Hendry P, et al. The impact of patient-prosthesis mismatch on late outcomes after mitral valve replacement. *J Thorac Cardiovasc Surg* 2007;133:1464-73.
52. Li M, Dumesnil JG, Mathieu P, Pibarot P. Impact of valve prosthesis-patient mismatch on pulmonary arterial pressure after mitral valve replacement. *J Am Coll Cardiol* 2005;45:1034-40.
53. Magne J, Mathieu P, Dumesnil JG, et al. Impact of prosthesis-patient mismatch on survival after mitral valve replacement. *Circulation* 2007;115:1417-25.
54. Mohty D, Dumesnil JG, Echahidi N, et al. Impact of prosthesis-patient mismatch on long-term survival after aortic valve replacement: influence of age, obesity, and left ventricular dysfunction. *J Am Coll Cardiol* 2009;53:39-47.
55. Bitar JN, Lechin ME, Salazar G, Zoghbi WA. Doppler echocardiographic assessment with the continuity equation of St. Jude Medical mechanical prostheses in the mitral valve position. *Am J Cardiol* 1995;76:287-93.
56. Ionescu A, Fraser AG, Butchart EG. Prevalence and clinical significance of incidental paraprosthetic valvar regurgitation: a prospective study using transoesophageal echocardiography. *Heart* 2003;89:1316-21.
57. O'Rourke DJ, Palac RT, Malenka DJ, Marrin CA, Arbuckle BE, Plehn JF. Outcome of mild periprosthetic regurgitation detected by intraoperative transesophageal echocardiography. *J Am Coll Cardiol* 2001;38:163-6.
58. Practice guidelines for perioperative transesophageal echocardiography. A report by the American Society of Anesthesiologists and the Society of Cardiovascular Anesthesiologists Task Force on Transesophageal Echocardiography. *Anesthesiology* 1996;84:986-1006.
59. Grewal KS, Malkowski MJ, Piracha AR, et al. Effect of general anesthesia on the severity of mitral regurgitation by transesophageal echocardiography. *Am J Cardiol* 2000;85:199-203.
60. Kubitz JC, Annecke T, Kemming GJ, et al. The influence of positive end-expiratory pressure on stroke volume variation and central blood volume during open and closed chest conditions. *Eur J Cardiothorac Surg* 2006;30:90-5.
61. McKinlay KH, Schindlerle DB, Swaminathan M, et al. Predictors of inotrope use during separation from cardiopulmonary bypass. *J Cardiothorac Vasc Anesth* 2004;18:404-8.
62. Schroeder RA, Mark JB. Is the valve OK or not? Immediate evaluation of a replaced aortic valve. *Anesth Analg* 2005;101:1288-91.
63. Reeves ST, Glas KE, Eltzschig H, et al. Guidelines for performing a comprehensive epicardial echocardiography examination: recommendations of the American Society of Echocardiography and the Society of Cardiovascular Anesthesiologists. *J Am Soc Echocardiogr* 2007;20:427-37.
64. Rizzoli G, Guglielmi C, Toscano G, et al. Reoperations for acute prosthetic thrombosis and pannus: an assessment of rates, relationship and risk. *Eur J Cardiothorac Surg* 1999;16:74-80.
65. Doenst T, Borger MA, David TE. Long-term results of bioprosthetic mitral valve replacement: the pericardial perspective. *J Cardiovasc Surg (Torino)* 2004;45:449-54.
66. Kilian E, Oberhoffer M, Gulbins H, Uhlig A, Kreuzer E, Reichart B. Ten years' experience in aortic valve replacement with homografts in 389 cases. *J Heart Valve Dis* 2004;13:554-9.
67. Zoghbi WA. Echocardiographic recognition of unusual complications after surgery on the great vessels and cardiac valves. In: Otto CM, editor. *The practice of clinical echocardiography*. New York: Elsevier; 2007: 605-26.
68. Birmingham GD, Rahko PS, Ballantyne F III. Improved detection of infective endocarditis with transesophageal echocardiography. *Am Heart J* 1992;123:774-81.



69. Daniel WG, Mugge A, Grote J, et al. Comparison of transthoracic and transesophageal echocardiography for detection of abnormalities of prosthetic and bioprosthetic valves in the mitral and aortic positions. *Am J Cardiol* 1993;71:210-5.
70. Karalis DG, Bansal RC, Hauck AJ, et al. Transesophageal echocardiographic recognition of subaortic complications in aortic valve endocarditis. Clinical and surgical implications. *Circulation* 1992;86:353-62.
71. Afridi I, Apostolidou MA, Saad RM, Zoghbi WA. Pseudoaneurysms of the mitral-aortic intervalvular fibrosa: dynamic characterization using transesophageal echocardiographic and Doppler techniques. *J Am Coll Cardiol* 1995;25:137-45.
72. Daniel WG, Mugge A, Martin RP, et al. Improvement in the diagnosis of abscesses associated with endocarditis by transesophageal echocardiography. *N Engl J Med* 1991;324:795-800.
73. Mugge A. Echocardiographic detection of cardiac valve vegetations and prognostic implications. *Infect Dis Clin North Am* 1993;7:877-98.
74. Baddour LM, Wilson WR, Bayer AS, et al. Infective endocarditis: diagnosis, antimicrobial therapy, and management of complications: a statement for healthcare professionals from the Committee on Rheumatic Fever, Endocarditis, and Kawasaki Disease, Council on Cardiovascular Disease in the Young, and the Councils on Clinical Cardiology, Stroke, and Cardiovascular Surgery and Anesthesia, American Heart Association: endorsed by the Infectious Diseases Society of America. *Circulation* 2005;111:e394-434.
75. Lowry RW, Zoghbi WA, Baker WB, Wray RA, Quinones MA. Clinical impact of transesophageal echocardiography in the diagnosis and management of infective endocarditis. *Am J Cardiol* 1994;73:1089-91.
76. Ali AS, Trivedi V, Lesch M. Culture-negative endocarditis—a historical review and 1990s update. *Prog Cardiovasc Dis* 1994;37:149-60.
77. Bayer AS. Infective endocarditis. *Clin Infect Dis* 1993;17:313-20.
78. Shively BK, Gurule FT, Roldan CA, Leggett JH, Schiller NB. Diagnostic value of transesophageal compared with transthoracic echocardiography in infective endocarditis. *J Am Coll Cardiol* 1991;18:391-7.
79. Gueret P, Vignon P, Fournier P, et al. Transesophageal echocardiography for the diagnosis and management of nonobstructive thrombosis of mechanical mitral valve prosthesis. *Circulation* 1995;91:103-10.
80. Isada LR, Torelli JN, Stewart WJ, Klein AL. Detection of fibrous strands on prosthetic mitral valves with transesophageal echocardiography: another potential embolic source. *J Am Soc Echocardiogr* 1994;7:641-5.
81. Orsinelli DA, Pearson AC. Detection of prosthetic valve strands by transesophageal echocardiography: clinical significance in patients with suspected cardiac source of embolism. *J Am Coll Cardiol* 1995;26:1713-8.
82. Barbetsas J, Nagueh SF, Pitsavos K, Toutouzas PK, Quinones MA, Zoghbi WA. Differentiating thrombus from pannus formation in obstructed mechanical prosthetic valves: an evaluation of clinical, transthoracic and transesophageal echocardiographic parameters. *J Am Coll Cardiol* 1998;32:1410-7.
83. Dzavik V, Cohen G, Chan KL. Role of transesophageal echocardiography in the diagnosis and management of prosthetic valve thrombosis. *J Am Coll Cardiol* 1991;18:1829-33.
84. Hurrell DC, Schaff HV, Tajik A. Thrombolytic therapy for obstruction of mechanical prosthetic valves. *Mayo Clin Proc* 1996;71:605-13.
85. Lengyel M, Fuster V, Keltai M, et al. Guidelines for management of left-sided prosthetic valve thrombosis: a role for thrombolytic therapy. Consensus Conference on Prosthetic Valve Thrombosis. *J Am Coll Cardiol* 1997;30:1521-6.
86. Tong AT, Roudaut R, Ozkan M, et al. Transesophageal echocardiography improves risk assessment of thrombolysis of prosthetic valve thrombosis: results of the international PRO-TEE registry. *J Am Coll Cardiol* 2004;43:77-84.
87. Zoghbi WA, Desir RM, Rosen L, Lawrie GM, Pratt CM, Quinones MA. Doppler echocardiography: application to the assessment of successful thrombolysis of prosthetic valve thrombosis. *J Am Soc Echocardiogr* 1989;2:98-101.
88. Donatelli F, Triggiani M, Mariani MA, et al. Rest and exercise hemodynamics of stentless porcine bioprostheses in aortic position. *Cardiologia* 1994;39:41-7.
89. Eriksson MJ, Brodin LA, Dellgren GN, Radegran K. Rest and exercise hemodynamics of an extended stentless aortic bioprosthesis. *J Heart Valve Dis* 1997;6:653-60.
90. Fries R, Wendler O, Schieffer H, Schafers HJ. Comparative rest and exercise hemodynamics of 23-mm stentless versus 23-mm stented aortic bioprostheses. *Ann Thorac Surg* 2000;69:817-22.
91. Jaffe WM, Coverdale HA, Roche AH, Whitlock RM, Neutze JM, Barratt-Boyes BG. Rest and exercise hemodynamics of 20 to 23 mm allograft, Medtronic Intact (porcine), and St. Jude Medical valves in the aortic position. *J Thorac Cardiovasc Surg* 1990;100:167-74.
92. Pibarot P, Dumesnil JG, Jobin J, Cartier P, Honos G, Durand LG. Hemodynamic and physical performance during maximal exercise in patients with an aortic bioprosthetic valve: comparison of stentless versus stented bioprostheses. *J Am Coll Cardiol* 1999;34:1609-17.
93. Chambers J, Rimington H, Rajani R, Hodson F, Blauth C. Hemodynamic performance on exercise: comparison of a stentless and stented biological aortic valve replacement. *J Heart Valve Dis* 2004;13:729-33.
94. Reis G, Motta MS, Barbosa MM, Esteves WA, Souza SF, Bocchi EA. Dobutamine stress echocardiography for noninvasive assessment and risk stratification of patients with rheumatic mitral stenosis. *J Am Coll Cardiol* 2004;43:393-401.
95. Castaneda-Zuniga W, Nicoloff D, Jorgensen C, Nath PH, Zollkofer C, Amplatz K. In vivo radiographic appearance of the St. Jude valve prosthesis. *Radiology* 1980;134:775-6.
96. Mehlmán DJ. A pictorial and radiographic guide for identification of prosthetic heart valve devices. *Prog Cardiovasc Dis* 1988;30:441-64.
97. White AF, Dinsmore RE, Buckley MJ. Cineradiographic evaluation of prosthetic cardiac valves. *Circulation* 1973;48:882-9.
98. Cohn LH, Collins JJ Jr, DiSesa VJ, et al. Fifteen-year experience with 1678 Hancock porcine bioprosthetic heart valve replacements. *Ann Surg* 1989;210:435-42.
99. Sands MJ Jr, Lachman AS, O'Reilly DJ, Leach CN Jr, Sappington JB, Katz AM. Diagnostic value of cinefluoroscopy in the evaluation of prosthetic heart valve dysfunction. *Am Heart J* 1982;104:622-7.
100. de Mol BA, Kallewaard M, McLellan RB, van Herwerden LA, Defauw JJ, van der GY. Single-leg strut fractures in explanted Bjork-Shiley valves. *Lancet* 1994;343:9-12.
101. Guit GL, van Voorthuisen AE, Steiner RM. Outlet strut fracture of the Bjork-Shiley mitral valve prosthesis. *Radiology* 1985;154:298.
102. Hiratzka LF, Kouchoukos NT, Grunkemeier GL, Miller DC, Scully HE, Wechsler AS. Outlet strut fracture of the Bjork-Shiley 60 degrees Convexo-Concave valve: current information and recommendations for patient care. *J Am Coll Cardiol* 1988;11:1130-7.
103. Odell JA, Durandt J, Shama DM, Vythilingum S. Spontaneous embolization of a St. Jude prosthetic mitral valve leaflet. *Ann Thorac Surg* 1985;39:569-72.
104. Piers LH, Dikkers R, Boonstra PW. Visualisation of a St Jude prosthetic mitral valve using electron beam tomography. *Heart* 2007;93:302.
105. Numata S, Okada H, Kitahara H, Kawazoe K. Four-dimensional evaluation of implanted mechanical valve with 64-row multi-detector computed tomography. *Eur J Cardiothorac Surg* 2007;31:934.
106. Leborgne L, Renard C, Tribouilloy C. Usefulness of ECG-gated multi-detector computed tomography for the diagnosis of mechanical prosthetic valve dysfunction. *Eur Heart J* 2006;27:2537.
107. Teshima H, Hayashida N, Enomoto N, Aoyagi S, Okuda K, Uchida M. Detection of pannus by multidetector-row computed tomography. *Ann Thorac Surg* 2003;75:1631-3.
108. Teshima H, Aoyagi S, Hayashida N, et al. Dysfunction of an ATS valve in the aortic position: the first reported case caused by pannus formation. *J Artif Organs* 2005;8:270-3.
109. Lembcke A, Hein PA, Enzweiler CN, Hoffmann U, Klessen C, Dohmen PM. Acute myocardial ischemia after aortic valve replacement: a comprehensive diagnostic evaluation using dynamic multislice spiral computed tomography. *Eur J Radiol* 2006;57:351-5.
110. Morgan-Hughes GJ, Owens PE, Roobottom CA, Marshall AJ. Three dimensional volume quantification of aortic valve calcification using multislice computed tomography. *Heart* 2003;89:1191-4.

111. Melina G, Horkaew P, Amrani M, Rubens MB, Yacoub MH, Yang GZ. Three-dimensional in vivo characterization of calcification in native valves and in Freestyle versus homograft aortic valves. *J Thorac Cardiovasc Surg* 2005;130:41-7.
112. Rashtian MY, Stevenson DM, Allen DT, et al. Flow characteristics of four commonly used mechanical heart valves. *Am J Cardiol* 1986;58:743-52.
113. Falicov RE, Walsh WF. Retrograde crossing of aortic Bjork-Shiley prosthesis. *Am J Cardiol* 1979;43:1062-4.
114. Karsh DL, Michaelson SP, Langou RA, Cohen LS, Wolfson S. Retrograde left ventricular catheterization in patients with an aortic valve prosthesis. *Am J Cardiol* 1978;41:893-6.
115. Kober G, Hilgermann R. Catheter entrapment in a Bjork-Shiley prosthesis in aortic position. *Cathet Cardiovasc Diagn* 1987;13:262-5.
116. Dunn M. Is transseptal catheterization necessary? *J Am Coll Cardiol* 1985;5:1393-4.
117. Horstkotte D, Haerten K, Seipel L, et al. Central hemodynamics at rest and during exercise after mitral valve replacement with different prostheses. *Circulation* 1983;68:11161-8.
118. Schoenfeld MH, Palacios IF, Hutter AM Jr, Jacoby SS, Block PC. Underestimation of prosthetic mitral valve areas: role of transseptal catheterization in avoiding unnecessary repeat mitral valve surgery. *J Am Coll Cardiol* 1985;5:1387-92.
119. Ben Zekry S, Saad RM, Little SH, Zoghbi WA. Flow acceleration time: a novel diagnostic parameter for prosthetic aortic valve stenosis [abstract]. *Circulation* 2008;118: S1069.
120. Chambers J, Rajani R, Hankins M, Cook R. The peak to mean pressure decrease ratio: a new method of assessing aortic stenosis. *J Am Soc Echocardiogr* 2005;18:674-8.
121. Rothbart RM, Castriz JL, Harding LV, Russo CD, Teague SM. Determination of aortic valve area by two-dimensional and Doppler echocardiography in patients with Normaland stenotic bioprosthetic valves. *J Am Coll Cardiol* 1990;15:817-24.
122. Otto CM, Pearlman AS, Comess KA, Reamer RP, Janko CL, Huntsman LL. Determination of the stenotic aortic valve area in adults using Doppler echocardiography. *J Am Coll Cardiol* 1986;7:509-17.
123. Zoghbi WA, Farmer KL, Soto JG, Nelson JG, Quinones MA. Accurate noninvasive quantification of stenotic aortic valve area by Doppler echocardiography. *Circulation* 1986;73:452-9.
124. Zabalgaitia M, Herrera CJ, Chaudhry FA, Calhoon JH, Mehlmán DJ, O'Rourke RA. Improvement in the diagnosis of bioprosthetic valve dysfunction by transesophageal echocardiography. *J Heart Valve Dis* 1993;2:595-603.
125. Saad RM, Barbetseas J, Olmos L, Rubio N, Zoghbi WA. Application of the continuity equation and valve resistance to the evaluation of St. Jude Medical prosthetic aortic valve dysfunction. *Am J Cardiol* 1997;80:1239-42.
126. Rajani R, Mukherjee D, Chambers JB. Doppler echocardiography in normally functioning replacement aortic valves: a review of 129 studies. *J Heart Valve Dis* 2007;16:519-35.
127. Rallidis LS, Moyssakis IE, Ikonomidis I, Nihoyannopoulos P. Natural history of early aortic paraprosthesis regurgitation: a five-year follow-up. *Am Heart J* 1999;138:351-7.
128. Kupferwasser I, Mohr-Kahaly S, Erbel R, et al. Improved assessment of pathological regurgitation in patients with prosthetic heart valves by multiplane transesophageal echocardiography. *Echocardiography* 1997;14:363-74.
129. Mohr-Kahaly S, Kupferwasser I, Erbel R, Oelert H, Meyer J. Regurgitant flow in apparently normal valve prostheses: improved detection and semiquantitative analysis by transesophageal two-dimensional color-coded Doppler echocardiography. *J Am Soc Echocardiogr* 1990;3:187-95.
130. Mohr-Kahaly S, Kupferwasser I, Erbel R, et al. Value and limitations of transesophageal echocardiography in the evaluation of aortic prostheses. *J Am Soc Echocardiogr* 1993;6:12-20.
131. Bach DS. Transesophageal echocardiographic (TEE) evaluation of prosthetic valves. *Cardiol Clin* 2000;18:751-71.
132. Sprecher DL, Adamick R, Adams D, Kisslo J. In vitro color flow, pulsed and continuous wave Doppler ultrasound masking of flow by prosthetic valves. *J Am Coll Cardiol* 1987;9:1306-10.
133. Muratori M, Montorsi P, Teruzzi G, et al. Feasibility and diagnostic accuracy of quantitative assessment of mechanical prostheses leaflet motion by transthoracic and transesophageal echocardiography in suspected prosthetic valve dysfunction. *Am J Cardiol* 2006;97:94-100.
134. Cohen GI, Davison MB, Klein AL, Salcedo EE, Stewart WJ. A comparison of flow convergence with other transthoracic echocardiographic indexes of prosthetic mitral regurgitation. *J Am Soc Echocardiogr* 1992;5:620-7.
135. Fernandes V, Olmos L, Nagueh SF, Quinones MA, Zoghbi WA. Peak early diastolic velocity rather than pressure half-time is the best index of mechanical prosthetic mitral valve function. *Am J Cardiol* 2002;89:704-10.
136. Baumgartner H, Schima H, Kuhn P. Discrepancies between Doppler and catheter gradients across bileaflet aortic valve prostheses. *Am J Cardiol* 1993;71:1241-3.
137. Yoganathan AP, Chau A, Gray RJ, et al. Bileaflet, tilting disc and porcine aortic valve substitutes: in vitro hydrodynamic characteristics. *J Am Coll Cardiol* 1984;3:313-20.
138. Goetze S, Brechtken J, Agler DA, Thomas JD, Sabik JF III, Jaber WA. In vivo short-term Doppler hemodynamic profiles of 189 Carpentier-Edwards Perimount pericardial bioprosthetic valves in the mitral position. *J Am Soc Echocardiogr* 2004;17:981-7.
139. Rosenhek R, Binder T, Maurer G, Baumgartner H. Normal values for Doppler echocardiographic assessment of heart valve prostheses. *J Am Soc Echocardiogr* 2003;16:1116-27.
140. Malouf JF, Ballo M, Connolly HM, et al. Doppler echocardiography of 119 normal-functioning St Jude Medical mitral valve prostheses: a comprehensive assessment including time-velocity integral ratio and prosthesis performance index. *J Am Soc Echocardiogr* 2005;18:252-6.
141. Panidis IP, Ross J, Mintz GS. Normal and abnormal prosthetic valve function as assessed by Doppler echocardiography. *J Am Coll Cardiol* 1986;8:317-26.
142. Malouf JF, Ballo M, Hodge DO, Herges RM, Orszulak TA, Miller FA Jr. Doppler echocardiography of normal Starr-Edwards mitral prostheses: a comprehensive function assessment including continuity equation and time-velocity integral ratio. *J Am Soc Echocardiogr* 2005;18:1399-403.
143. Blauwet LA, Malouf JF, Connolly HM, et al. Doppler echocardiography of 79 normal CarboMedics mitral prostheses: a comprehensive assessment including time-velocity integral ratio and prosthesis performance index. *J Am Soc Echocardiogr* 2009;20:1125-30.
144. Blauwet LA, Malouf JF, Connolly HM, et al. Doppler echocardiography of 240 normal Carpentier-Edwards Duraflex porcine mitral bioprostheses: a comprehensive assessment including time velocity integral ratio and prosthesis performance index. *J Am Soc Echocardiogr* 2009;22:388-93.
145. Davila-Roman VG, Waggoner AD, Kennard ED, et al. Prevalence and severity of paravalvular regurgitation in the Artificial Valve Endocarditis Reduction Trial (AVERT) echocardiography study. *J Am Coll Cardiol* 2004;44:1467-72.
146. Montorsi P, Cavoretto D, Parolari A, Muratori M, Alimento M, Pepi M. Diagnosing prosthetic mitral valve thrombosis and the effect of the type of prosthesis. *Am J Cardiol* 2002;90:73-6.
147. Ronderos RE, Portis M, Stoermann W, Sarmiento C. Are all echocardiographic findings equally predictive for diagnosis in prosthetic endocarditis? *J Am Soc Echocardiogr* 2004;17:664-9.
148. Olmos L, Salazar G, Barbetseas J, Quinones MA, Zoghbi WA. Usefulness of transthoracic echocardiography in detecting significant prosthetic mitral valve regurgitation. *Am J Cardiol* 1999;83:199-205.
149. Alton ME, Pasierski TJ, Orsinelli DA, Eaton GM, Pearson AC. Comparison of transthoracic and transesophageal echocardiography in evaluation of 47 Starr-Edwards prosthetic valves. *J Am Coll Cardiol* 1992;20:1503-11.

150. Daniel LB, Grigg LE, Weisel RD, Rakowski H. Comparison of transthoracic and transesophageal assessment of prosthetic valve dysfunction. *Echocardiography* 1990;7:83-95.
151. Flachskampf FA, Hoffmann R, Franke A, et al. Does multiplane transesophageal echocardiography improve the assessment of prosthetic valve regurgitation? *J Am Soc Echocardiogr* 1995;8:70-8.
152. Hung J, Lang RM, Flachskampf FA, et al. 3D echocardiography: a review of the current status and future directions. *J Am Soc Echocardiogr* 2007;20:213-33.
153. Fischer CH, Campos FO, Moises VA, et al. Quantification of mitral prosthesis failure by different methods of evaluation by transesophageal echocardiography. *Arq Bras Cardiol* 1998;71:741-5.
154. Vitarelli A, Conde Y, Cimino E, et al. Assessment of severity of mechanical prosthetic mitral regurgitation by transoesophageal echocardiography. *Heart* 2004;90:539-44.
155. Genoni M, Franzen D, Tavakoli R, et al. Does the morphology of mitral paravalvular leaks influence symptoms and hemolysis? *J Heart Valve Dis* 2001;10:426-30.
156. Meliones JN, Snider AR, Bove EL, et al. Doppler evaluation of homograft valved conduits in children. *Am J Cardiol* 1989;64:354-8.
157. Novaro GM, Connolly HM, Miller FA. Doppler hemodynamics of 51 clinically and echocardiographically normal pulmonary valve prostheses. *Mayo Clin Proc* 2001;76:155-60.
158. da Costa F, Haggi H, Pinton R, Lenke W, Adam E, Costa IS. Rest and exercise hemodynamics after the Ross procedure: an echocardiographic study. *J Card Surg* 1998;13:177-85.
159. Moidl R, Simon P, Kupilik N, et al. Increased pulmonary flow velocities in oversized homografts in patients after the Ross procedure. *Eur J Cardiothorac Surg* 1997;12:569-72.
160. Ward KE, Elkins RC, Overholt ED, et al. Evaluation of cryopreserved homografts in the right ventricular outflow tract after the Ross procedure: intermediate-term follow up. *J Heart Valve Dis* 1997;6:130-3.
161. Briand M, Pibarot P, Dumesnil JG, Cartier P. Midterm echocardiographic follow-up after Ross operation. *Circulation* 2000;102:III10-4.
162. Rosti L, Murzi B, Colli AM, et al. Mechanical valves in the pulmonary position: a reappraisal. *J Thorac Cardiovasc Surg* 1998;115:1074-9.
163. Waterbolk TW, Hoendermis ES, den H I, Ebels T. Pulmonary valve replacement with a mechanical prosthesis. Promising results of 28 procedures in patients with congenital heart disease. *Eur J Cardiothorac Surg* 2006;30:28-32.
164. Cooper J. Conventional and color Doppler assessment of right-sided valvular regurgitation. In: Nanda NK, editor. *Textbook of color Doppler echocardiography*. Philadelphia: Lea & Febiger; 1989:160-7.
165. Rao PS, Galal O, Patnana M, Buck SH, Wilson AD. Results of three to 10 year follow up of balloon dilatation of the pulmonary valve. *Heart* 1998;80:591-5.
166. Allen BS, El-Zein C, Cuneo B, Cava JP, Barth MJ, Ilbawi MN. Pericardial tissue valves and Gore-Tex conduits as an alternative for right ventricular outflow tract replacement in children. *Ann Thorac Surg* 2002;74:771-7.
167. Kanter KR, Budde JM, Parks WJ, et al. One hundred pulmonary valve replacements in children after relief of right ventricular outflow tract obstruction. *Ann Thorac Surg* 2002;73:1801-6.
168. Kanter KR, Fyfe DA, Mahle WT, Forbess JM, Kirshbom PM. Results with the freestyle porcine aortic root for right ventricular outflow tract reconstruction in children. *Ann Thorac Surg* 2003;76:1889-94.
169. Koh M, Yagihara T, Uemura H, et al. Long-term outcome of right ventricular outflow tract reconstruction using a handmade tri-leaflet conduit. *Eur J Cardiothorac Surg* 2005;27:807-14.
170. Marx GR, Hicks RW, Allen HD, Goldberg SJ. Noninvasive assessment of hemodynamic responses to exercise in pulmonary regurgitation after operations to correct pulmonary outflow obstruction. *Am J Cardiol* 1988;61:595-601.
171. Settepani F, Kaya A, Morshuis WJ, Schepens MA, Heijmen RH, Dossche KM. The Ross operation: an evaluation of a single institution's experience. *Ann Thorac Surg* 2005;79:499-504.
172. Sievers HH, Dahmen G, Graf B, Stierle U, Ziegler A, Schmidtke C. Midterm Results of the Ross procedure preserving the patient's aortic root [abstract]. *Circulation* 2003;108:55-60.
173. Weyman AE. Right ventricular outflow tract. In: Weyman AE, editor. *Principles and practices of echocardiography*. Philadelphia: Lea & Febiger; 1994:863-900.
174. Chan KC, Fyfe DA, McKay CA, Sade RM, Crawford FA. Right ventricular outflow reconstruction with cryopreserved homografts in pediatric patients: intermediate-term follow-up with serial echocardiographic assessment. *J Am Coll Cardiol* 1994;24:483-9.
175. Goldberg SJ, Allen HD. Quantitative assessment by Doppler echocardiography of pulmonary or aortic regurgitation. *Am J Cardiol* 1985;56:131-5.
176. Connolly HM, Miller FA Jr, Taylor CL, Naessens JM, Seward JB, Tajik AJ. Doppler hemodynamic profiles of 82 clinically and echocardiographically normal tricuspid valve prostheses. *Circulation* 1993;88:2722-7.
177. Kobayashi Y, Nagata S, Ohmori F, Eishi K, Nakano K, Miyatake K. Serial Doppler echocardiographic evaluation of bioprosthetic valves in the tricuspid position. *J Am Coll Cardiol* 1996;27:1693-7.
178. Aoyagi S, Nishi Y, Kawara T, Oryoji A, Kosuga K, Ohishi K. Doppler echocardiographic evaluation of St. Jude Medical valves in the tricuspid position. *J Heart Valve Dis* 1993;2:279-86.
179. Kocis KC, Snider AR, Lupinetti FM, Bove EL. Doppler forward flow profiles of St. Jude Medical prosthetic valves in pediatric patients. *Am J Cardiol* 1994;74:77-9.
180. Masuda M, Kado H, Tatewaki H, Shiokawa Y, Yasui H. Late results after mitral valve replacement with bileaflet mechanical prosthesis in children: evaluation of prosthesis-patient mismatch. *Ann Thorac Surg* 2004;77:913-7.
181. Karamlou T, Jang K, Williams WG, et al. Outcomes and associated risk factors for aortic valve replacement in 160 children: a competing-risks analysis. *Circulation* 2005;112:3462-9.
182. Adatia I, Moore PM, Jonas RA, Colan SD, Lock JE, Keane JF. Clinical course and hemodynamic observations after supraannular mitral valve replacement in infants and children. *J Am Coll Cardiol* 1997;29:1089-94.
183. Dinarevic S, Redington A, Rigby M, Sheppard MN. Left ventricular pannus causing inflow obstruction late after mitral valve replacement for endocardial fibroelastosis. *Pediatr Cardiol* 1996;17:257-9.
184. Sugeng L, Sherman SK, Weinert L, et al. Real-time three-dimensional transesophageal echocardiography in valve disease: comparison with surgical findings and evaluation of prosthetic valves. *J Am Soc Echocardiogr* 2009;21:1347-54.
185. Little SH, Ben Zekry S, Zoghbi WA, Kleiman NS, Guthikonda S. Three-dimensional transesophageal echocardiogram provides real-time guidance during percutaneous paravalvular mitral repair. *Cir Heart Fail* 2009;1:293-4.

## Appendix A. Normal Doppler Echocardiographic Values for Prosthetic Aortic Valves\*

Valve	Size	Peak gradient (mm Hg)	Mean gradient (mmHg)	Effective orifice area (cm <sup>2</sup> )
ATS <i>Bileaflet</i>	19	47.0± 12.6	25.3± 8.0	1.1± 0.3
	21	23.7± 6.8	15.9± 5.0	1.4± 0.5
	23		14.4± 4.9	1.7± 0.5
	25		11.3± 3.7	2.1± 0.7
	27		8.4± 3.7	2.5± 0.1
	29		8.0± 3.0	3.1± 0.8
ATS AP <i>Bileaflet</i>	18		21.0± 1.8	1.2± 0.3
	20	21.4± 4.2	11.1± 3.5	1.3± 0.3
	22	18.7± 8.3	10.5± 4.5	1.7± 0.4
	24	15.1± 5.6	7.5± 3.1	2.0± 0.6
Baxter Perimount <i>Stented bovine pericardial</i>	26		6.0± 2.0	2.1± 0.4
	19	32.5± 8.5	19.5± 5.5	1.3± 0.2
	21	24.9± 7.7	13.8± 4.0	1.3± 0.3
	23	19.9± 7.4	11.5± 3.9	1.6± 0.3
	25	16.5± 7.8	10.7± 3.8	1.6± 0.4
Biocor <i>Stented porcine</i>	27	12.8± 5.4	4.8± 2.2	2.0± 0.4
	23	30.0± 10.7	20± 6.6	1.3± 0.3
	25	23.0± 7.9	16± 5.1	1.7± 0.4
Extended Biocor <i>Stentless</i>	27	22.0± 6.5	15.0± 3.7	2.2± 0.4
	19-21	17.5± 6.5	9.6± 3.6	1.4± 0.4
	23	14.7± 7.3	7.7± 3.8	1.7± 0.4
Bioflo <i>Stented bovine pericardial</i>	25	14.0± 4.3	7.4± 2.5	1.8± 0.4
	19	37.2± 8.8	26.4± 5.5	0.7± 0.1
	21	28.7± 6.2	18.7± 5.5	1.1± 0.1
Bjork-Shiley <i>Single tilting disc</i>	21	38.9± 11.9	21.8± 3.4	1.1± 0.3
	23	28.8± 11.2	15.7± 5.3	1.3± 0.3
	25	23.7± 8.2	13.0± 5.0	1.5± 0.4
	27		10.0± 2.0	1.6± 0.3
Carbomedics Reduced <i>Bileaflet</i>	19	43.4± 1.2	24.4± 1.2	1.2± 0.1
Carbomedics Standard <i>Bileaflet</i>	19	38.0± 12.8	18.9± 8.3	1.0± 0.3
	21	26.8± 10.1	12.9± 5.4	1.5± 0.4
	23	22.5± 7.4	11.0± 4.6	1.4± 0.3
	25	19.6± 7.8	9.1± 3.5	1.8± 0.4
	27	17.5± 7.1	7.9± 3.2	2.2± 0.2
	29	9.1± 4.7	5.6± 3.0	3.2± 1.6
Carbomedics Tophat <i>Bileaflet</i>	21	30.2± 10.9	14.9± 5.4	1.2± 0.3
	23	24.2± 7.6	12.5± 4.4	1.4± 0.4
	25		9.5± 2.9	1.6± 0.32
Carpentier Edwards <i>Pericardial Stented bovine pericardial</i>	19	32.1± 3.4	24.2± 8.6	1.2± 0.3
	21	25.7± 9.9	20.3± 9.1	1.5± 0.4
	23	21.7± 8.6	13.0± 5.3	1.8± 0.3
	25	16.5± 5.4	9.0± 2.3	
Carpentier Edwards Standard <i>Stented porcine</i>	19	43.5± 12.7	25.6± 8.0	0.9± 0.2
	21	27.7± 7.6	17.3± 6.2	1.5± 0.3
	23	28.9± 7.5	16.1± 6.2	1.7± 0.5
	25	24.0± 7.1	12.9± 4.6	1.9± 0.5
	27	22.1± 8.2	12.1± 5.5	2.3± 0.6
Carpentier Supra-Annular <i>Stented porcine</i>	29		9.9± 2.9	2.8± 0.5
	19	34.1± 2.7		1.1± 0.1
	21	28.0± 10.5	17.5± 3.8	1.4± 0.9
	23	25.3± 10.5	13.4± 4.5	1.6± 0.6
	25	24.4± 7.6	13.2± 4.8	1.8± 0.4
27	16.7± 4.7	8.8± 2.8	1.9± 0.7	

Appendix A. (Continued)

Cryolife <i>Stentless</i>	19		9.0± 2.0	1.5± 0.3
	21		6.6± 2.9	1.7± 0.4
	23		6.0± 2.3	2.3± 0.2
	25		6.1± 2.6	2.6± 0.2
	27		4.0± 2.4	2.8± 0.3
Edwards Duromedics <i>Bileaflet</i>	21	39.0± 13		
	23	32.0± 8.0		
	25	26.0± 10.0		
	27	24.0± 10.0		
Edwards Mira <i>Bileaflet</i>	19		18.2± 5.3	1.2± 0.4
	21		13.3± 4.3	1.6± 0.4
	23		14.7± 2.8	1.6± 0.6
	25		13.1± 3.8	1.9
Hancock <i>Stented porcine</i>	21	18.0± 6.0	12.0± 2.0	
	23	16.0± 2.0	11.0± 2.0	
	25	15.0± 3.0	10.0± 3.0	
Hancock II <i>Stented porcine</i>	21		14.8± 4.1	1.3± 0.4
	23	34.0± 13.0	16.6± 8.5	1.3± 0.4
	25	22.0± 5.3	10.8± 2.8	1.6± 0.4
	29	16.2± 1.5	8.2± 1.7	1.6± 0.2
Homograft <i>Homograft valves</i>	17-19		9.7± 4.2	4.2± 1.8
	19-21			5.4± 0.9
	20-21		7.9± 4.0	3.6± 2.0
	20-22		7.2± 3.0	3.5± 1.5
	22	1.7± 0.3		5.8± 3.2
	22-23		5.6± 3.1	2.6± 1.4
	22-24			5.6± 1.7
	24-27		6.2± 2.6	2.8± 1.1
	26	1.4± 0.6		6.8± 2.9
25-28			6.2± 2.5	
Intact <i>Stented porcine</i>	19	40.4± 15.4	24.5± 9.3	
	21	40.9± 15.6	19.6± 8.1	1.6± 0.4
	23	32.7± 9.6	19.0± 6.1	1.6± 0.4
	25	29.7± 15.0	17.7± 7.9	1.7± 0.3
	27	25.0± 7.6	15.0± 4.5	
Ionescu-Shiley <i>Stented bovine pericardial</i>	17	23.8± 3.4		0.9± 0.1
	19	19.7± 5.9	13.3± 3.9	1.1± 0.1
	21	26.6± 9.0		
Labcor Santiago <i>Stented bovine pericardial</i>	23		15.6± 4.4	
	19	18.6± 5.0	11.8± 3.3	1.2± 0.1
	21	17.5± 6.6	8.2± 4.5	1.3± 0.1
	23	14.8± 5.2	7.8± 2.9	1.8± 0.2
Labcor Synergy <i>Stented porcine</i>	25	12.3± 3.4	6.8± 2.0	2.1± 0.3
	21	24.3± 8.1	13.3± 4.2	1.1± 0.3
	23	27.3± 13.7	15.3± 6.9	1.4± 0.4
	25	22.5± 11.9	13.2± 6.4	1.5± 0.4
MCRI On-X <i>Bileaflet</i>	27	17.8± 7.0	10.6± 4.6	1.8± 0.5
	19	21.3± 10.8	11.8± 3.4	1.5± 0.2
	21	16.4± 5.9	9.9± 3.6	1.7± 0.4
	23	15.9± 6.4	8.6± 3.4	1.9± 0.6
Medtronic Advantage <i>Bileaflet</i>	25	16.5± 10.2	6.9± 4.3	2.4± 0.6
	23		10.4± 3.1	2.2± 0.3
	25		9.0± 3.7	2.8± 0.6
	27		7.6± 3.6	3.3± 0.7
Medtronic Freestyle <i>Stentless</i>	29		6.1± 3.8	3.9± 0.7
	19		13.0± 3.9	
	21		9.1± 5.1	1.4± 0.3
	23	11.0± 4.0	8.1± 4.6	1.7± 0.5
	25		5.3± 3.1	2.1± 0.5
	27		4.6± 3.1	2.5± 0.1

Appendix A. (Continued)		20	34.4± 13.1	17.1± 5.3	1.2± 0.5
	Medtronic Hall <i>Single tilting disc</i>	21	26.9± 10.5	14.1± 5.9	1.1± 0.2
		23	26.9± 8.9	13.5± 4.8	1.4± 0.4
		25	17.1± 7.0	9.5± 4.3	1.5± 0.5
		27	18.9± 9.7	8.7± 5.6	1.9± 0.2
Medtronic Mosaic <i>Stented porcine</i>	21		14.2± 5.0	1.4± 0.4	
	23	23.8± 11.0	13.7± 4.8	1.5± 0.4	
	25	22.5± 10.0	11.7± 5.1	1.8± 0.5	
	27		10.4± 4.3	1.9± 0.1	
	29		11.1± 4.3	2.1± 0.2	
Mitroflow <i>Stented bovine pericardial</i>	19	18.6± 5.3	13.1± 3.3	1.1± 0.2	
Monostrut Bjork-Shiley <i>Single tilting disc</i>	19		27.4± 8.8		
	21	27.5± 3.1	20.5± 6.2		
	23	20.3± 0.7	17.4± 6.4		
	25		16.1± 4.9		
	27		11.4± 3.8		
Prima <i>Stentless</i>	21	28.8± 6.0	13.7± 1.9	1.4± 0.7	
	23	21.5± 7.5	11.5± 4.9	1.5± 0.3	
	25	22.1± 12.5	11.6± 7.2	1.8± 0.5	
Omnicarbon <i>Single tilting disc</i>	21	37.4± 12.8	20.4± 5.4	1.3± 0.5	
	23	28.8± 9.1	17.4± 4.9	1.5± 0.3	
	25	23.7± 8.1	13.2± 4.6	1.9± 0.5	
	27	20.1± 4.2	12.4± 2.9	2.1± 0.4	
Omniscience <i>Single tilting disc</i>	21	50.8± 2.8	28.2± 2.2	0.9± 0.1	
	23	39.8± 8.7	20.1± 5.1	1.0± 0.1	
Starr Edwards <i>Caged ball</i>	23	32.6± 12.8	22.0± 9.0	1.1± 0.2	
	24	34.1± 10.3	22.1± 7.5	1.1± 0.3	
	26	31.8± 9.0	19.7± 6.1		
	27	30.8± 6.3	18.5± 3.7		
	29	29.0± 9.3	16.3± 5.5		
Sorin Bicarbon <i>Bileaflet</i>	19	30.1± 4.5	16.7± 2.0	1.4± 0.1	
	21	22.0± 7.1	10.0± 3.3	1.2± 0.4	
	23	16.8± 6.1	7.7± 3.3	1.5± 0.2	
	25	11.2± 3.1	5.6± 1.6	2.4± 0.3	
Sorin Pericarbon <i>Stentless</i>	19	36.5± 9.0	28.9± 7.3	1.2± 0.5	
	21	28.0± 13.3	23.8± 11.1	1.3± 0.6	
	23	27.5± 11.5	23.2± 7.6	1.5± 0.5	
St. Jude Medical Haem Plus <i>Bileaflet</i>	19	28.5± 10.7	17.0± 7.8	1.9± 0.1	
	21	16.3± 17.0	10.6± 5.1)	1.8± 0.5	
	23	16.8± 7.3	12.1± 4.2	1.7± 0.5	
St Jude Medical Regent <i>Bileaflet</i>	19	20.6± 12	11.0± 4.9	1.6± 0.4	
	21	15.6± 9.4	8.0± 4.8	2.0± 0.7	
	23	12.8± 6.8	6.9± 3.5	2.3± 0.9	
	25	11.7± 6.8	5.6± 3.2	2.5± 0.8	
St Jude Medical Standard <i>Bileaflet</i>	27	7.9± 5.5	3.5± 1.7	3.6± 0.5	
	19	42.0± 10.0	24.5± 5.8	1.5± 0.1	
	21	25.7± 9.5	15.2± 5.0	1.4± 0.4	
	23	21.8± 7.5	13.4± 5.6	1.6± 0.4	
	25	18.9± 7.3	11.0± 5.3	1.9± 0.5	
St Jude Medical <i>Stentless</i>	27	13.7± 4.2	8.4± 3.4	2.5± 0.4	
	29	13.5± 5.8	7.0± 1.7	2.8± 0.5	
	21	22.6± 14.5	10.7± 7.2	1.3± 0.6	
	23	16.2± 9.0	8.2± 4.7	1.6± 0.6	
	25	12.7± 8.2	6.3± 4.1	1.8± 0.5	
	27	10.1± 5.8	5.0± 2.9	2.0± 0.3	
	29	7.7± 4.4	4.1± 2.4	2.4± 0.6	

\*Modified from Rajani et al.<sup>126</sup>

**Appendix B. Normal Doppler Echocardiography Values for Prosthetic Mitral Valves\***

Valve	Size	Peak gradient (mm Hg)	Mean gradient (mm Hg)	Peak velocity (m/s)	Pressure half-time (ms)	Effective orifice area (cm <sup>2</sup> )
Biocor <i>Stentless bioprosthesis</i>	27	13 ± 1				
	29	14 ± 2.5				
	31	11.5 ± 0.5				
	33	12 ± 0.5				
Bioflo pericardial <i>Stented bioprosthesis</i>	25	10 ± 2	6.3 ± 1.5			2 ± 0.1
	27	9.5 ± 2.6	5.4 ± 1.2			2 ± 0.3
	29	5 ± 2.8	3.6 ± 1			2.4 ± 0.2
	31	4.0	2.0			2.3
Bjork-Shiley <i>Tilting disc</i>	23			1.7	115	
	25	12 ± 4	6 ± 2	1.75 ± 0.38	99 ± 27	1.72 ± 0.6
	27	10 ± 4	5 ± 2	1.6 ± 0.49	89 ± 28	1.81 ± 0.54
	29	7.83 ± 2.93	2.83 ± 1.27	1.37 ± 0.25	79 ± 17	2.1 ± 0.43
	31	6 ± 3	2 ± 1.9	1.41 ± 0.26	70 ± 14	2.2 ± 0.3
Bjork-Shiley monostrut <i>Tilting disc</i>	23		5.0	1.9		
	25	13 ± 2.5	5.57 ± 2.3	1.8 ± 0.3		
	27	12 ± 2.5	4.53 ± 2.2	1.7 ± 0.4		
	29	13 ± 3	4.26 ± 1.6	1.6 ± 0.3		
	31	14 ± 4.5	4.9 ± 1.6	1.7 ± 0.3		
Carbomedics <i>Bileaflet</i>	23			1.9 ± 0.1	126 ± 7	
	25	10.3 ± 2.3	3.6 ± 0.6	1.3 ± 0.1	93 ± 8	2.9 ± 0.8
	27	8.79 ± 3.46	3.46 ± 1.03	1.61 ± 0.3	89 ± 20	2.9 ± 0.75
	29	8.78 ± 2.9	3.39 ± 0.97	1.52 ± 0.3	88 ± 17	2.3 ± 0.4
	31	8.87 ± 2.34	3.32 ± 0.87	1.61 ± 0.29	92 ± 24	2.8 ± 1.14
Carpentier- Edwards <i>Stented bioprosthesis</i>	27		6 ± 2	1.7 ± 0.3	98 ± 28	
	29		4.7 ± 2	1.76 ± 0.27	92 ± 14	
	31		4.4 ± 2	1.54 ± 0.15	92 ± 19	
	33		6 ± 3		93 ± 12	
Carpentier- Edwards pericardial <i>Stented Bioprosthesis</i>	27		3.6	1.6	100	
	29		5.25 ± 2.36	1.67 ± 0.3	110 ± 15	
	31		4.05 ± 0.83	1.53 ± 0.1	90 ± 11	
	33		1.0	0.8	80	
Duromedics <i>Bileaflet</i>	27	13 ± 6	5 ± 3	1.61 ± 0.4	75 ± 12	
	29	10 ± 4	3 ± 1	1.40 ± 0.25	85 ± 22	
	31	10.5 ± 4.33	3.3 ± 1.36	1.38 ± 0.27	81 ± 12	
	33	11.2	2.5		85	
Hancock I or not specified <i>Stented bioprosthesis</i>	27	10 ± 4	5 ± 2			1.3 ± 0.8
	29	7 ± 3	2.46 ± 0.79		115 ± 20	1.5 ± 0.2
	31	4 ± 0.86	4.86 ± 1.69		95 ± 17	1.6 ± 0.2
	33	3 ± 2	3.87 ± 2		90 ± 12	1.9 ± 0.2
Hancock II <i>Stented bioprosthesis</i>	27					2.21 ± 0.14
	29					2.77 ± 0.11
	31					2.84 ± 0.1
	33					3.15 ± 0.22
Hancock pericardial <i>Stented bioprosthesis</i>	29		2.61 ± 1.39	1.42 ± 0.14	105 ± 36	
	31		3.57 ± 1.02	1.51 ± 0.27	81 ± 23	
Ionescu-Shiley <i>Stented bioprosthesis</i>	25		4.87 ± 1.08	1.43 ± 0.15	93 ± 11	
	27		3.21 ± 0.82	1.31 ± 0.24	100 ± 28	
	29		3.22 ± 0.57	1.38 ± 0.2	85 ± 8	
	31		3.63 ± 0.9	1.45 ± 0.06	100 ± 36	

## Appendix B. (Continued)

Ionescu-Shiley low profile	29		3.31 ± 0.96	1.36 ± 0.25	80 ± 30	
Stented bioprosthesis	31		2.74 ± 0.37	1.33 ± 0.14	79 ± 15	
Labcor-Santiago pericardial	25	8.7	4.5		97	2.2
Stented bioprosthesis	27	5.6 ± 2.3	2.8 ± 1.5		85 ± 18	2.12 ± 0.48
	29	6.2 ± 2.1	3 ± 1.3		80 ± 34	2.11 ± 0.73
	18			1.7	140	
Lillehei- Kaster Tilting disc	20			1.7	67	
	22			1.56 ± 0.09	94 ± 22	
	25			1.38 ± 0.27	124 ± 46	
	27			1.4	78	
Medtronic- Hall Tilting disc	29			1.57 ± 0.1	69 ± 15	
	31			1.45 ± 0.12	77 ± 17	
	29		3.5 ± 0.51	1.6 ± 0.22		
Medtronic Intact Porcine Stented bioprosthesis	31		4.2 ± 1.44	1.6 ± 0.26		
	33		4 ± 1.3	1.4 ± 0.24		
	35		3.2 ± 1.77	1.3 ± 0.5		
	25		6.9	2.0	90	
Mitroflow Stented bioprosthesis	27		3.07 ± 0.91	1.5	90 ± 20	
	29		3.5 ± 1.65	1.43 ± 0.29	102 ± 21	
	31		3.85 ± 0.81	1.32 ± 0.26	91 ± 22	
	23		8.0			
	25		6.05 ± 1.81	1.77 ± 0.24	102 ± 16	
Omnicarbon Tilting disc	27		4.89 ± 2.05	1.63 ± 0.36	105 ± 33	
	29		4.93 ± 2.16	1.56 ± 0.27	120 ± 40	
	31		4.18 ± 1.4	1.3 ± 0.23	134 ± 31	
	33		4 ± 2			
	25	11.5 ± 3.2	5.3 ± 2.1			1.9 ± 1.1
On-X Bileaflet	27-29	10.3 ± 4.5	4.5 ± 1.6			2.2 ± 0.5
	31-33	9.8 ± 3.8	4.8 ± 2.4			2.5 ± 1.1
	25	15 ± 3	5 ± 1	2 ± 0.2	105 ± 29	2.2 ± 0.6
Sorin Allcarbon Tilting disc	27	13 ± 2	4 ± 1	1.8 ± 0.1	89 ± 14	2.5 ± 0.5
	29	10 ± 2	4 ± 1	1.6 ± 0.2	85 ± 23	2.8 ± 0.7
	31	9 ± 1	4 ± 1	1.6 ± 0.1	88 ± 27	2.8 ± 0.9
	25	15 ± 0.25	4 ± 0.5	1.95 ± 0.02	70 ± 1	
Sorin Bicarbon Bileaflet	27	11 ± 2.75	4 ± 0.5	1.65 ± 0.21	82 ± 20	
	29	12 ± 3	4 ± 1.25	1.73 ± 0.22	80 ± 14	
	31	10 ± 1.5	4 ± 1	1.66 ± 0.11	83 ± 14	
	23		4.0	1.5	160	1.0
	25		2.5 ± 1	1.34 ± 1.12	75 ± 4	1.35 ± 0.17
St Jude Medical Bileaflet	27	11 ± 4	5 ± 1.82	1.61 ± 0.29	75 ± 10	1.67 ± 0.17
	29	10 ± 3	4.15 ± 1.8	1.57 ± 0.29	85 ± 10	1.75 ± 0.24
	31	12 ± 6	4.46 ± 2.22	1.59 ± 0.33	74 ± 13	2.03 ± 0.32
	26		10.0			1.4
	28		7 ± 2.75			1.9 ± 0.57
Starr- Edwards Caged ball	30	12.2 ± 4.6	6.99 ± 2.5	1.7 ± 0.3	125 ± 25	1.65 ± 0.4
	32	11.5 ± 4.2	5.08 ± 2.5	1.7 ± 0.3	110 ± 25	1.98 ± 0.4
	34		5.0			2.6
Stentless quadrileaflet bovine pericardial Stentless bioprosthesis	26		2.2 ± 1.7	1.6	103 ± 31	1.7
	28			1.58 ± 0.25		1.7 ± 0.6
	30			1.42 ± 0.32		2.3 ± 0.4
Wessex Stented bioprosthesis	29		3.69 ± 0.61	1.66 ± 0.17	83 ± 19	
	31		3.31 ± 0.83	1.41 ± 0.25	80 ± 21	

\*modified from Rosenhek, et al.<sup>139</sup>